

Methods of Cognitive Neuroscience

Focus on Language

Likan Zhan

Beijing Language and Culture University

2018-11-27

zhanlikan@blcu.edu.cn

Table of Contents

1. Studying the Damaged Brain
2. Perturbing Neural Function
3. Studying Neural function
4. Analyzing the Brain Structure
5. Neuroimaging: Function + Structure
6. Summary

References

Studying the Damaged Brain

Studying the Damaged Brain

Causes of Neurological Dysfunction

Causes of Neurological Dysfunction

Causes of Neurological Dysfunction

- Vascular Disorders (血管问题)

Causes of Neurological Dysfunction

- Vascular Disorders (血管问题)
- Tumors (肿瘤)

Causes of Neurological Dysfunction

- Vascular Disorders (血管问题)
- Tumors (肿瘤)
- Degenerative and Infectious Disorders (退行性和传染性疾病)

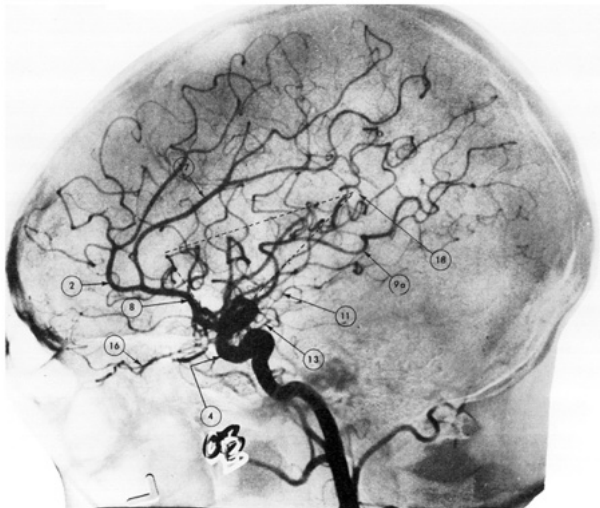Causes of Neurological Dysfunction

- Vascular Disorders (血管问题)
- Tumors (肿瘤)
- Degenerative and Infectious Disorders (退行性和传染性疾病)
- Traumatic Brain Injury (外伤性脑损伤)

Causes of Neurological Dysfunction

- Vascular Disorders (血管问题)
- Tumors (肿瘤)
- Degenerative and Infectious Disorders (退行性和传染性疾病)
- Traumatic Brain Injury (外伤性脑损伤)
- Epilepsy (癫痫病)

The brain's blood supply



Angiography (血管造影术) (DeArmond, Fusco, & Dewey, 1989)

Vascular Disorders

Vascular Disorders

- Atherosclerosis (动脉硬化), embolus (血栓)

Vascular Disorders

- Atherosclerosis (动脉硬化), embolus (血栓)
- Cerebral vascular accidents, or stroke (中风):
Blood flow to the brain is suddenly disrupted.

Vascular Disorders

- Atherosclerosis (动脉硬化), embolus (血栓)
- Cerebral vascular accidents, or stroke (中风):
Blood flow to the brain is suddenly disrupted.
- Ischemia (脑出血)

Tumors

Tumors

- A tumor, or neoplasm, is a mass of tissue that grows abnormally and has no physiological function.

Tumors

- A tumor, or neoplasm, is a mass of tissue that grows abnormally and has no physiological function.
- Glial cells and other supporting white matter tissues.

Tumors

- A tumor, or neoplasm, is a mass of tissue that grows abnormally and has no physiological function.
- Glial cells and other supporting white matter tissues.
- Benign (良性的) vs Malignant or cancerous (恶性的)

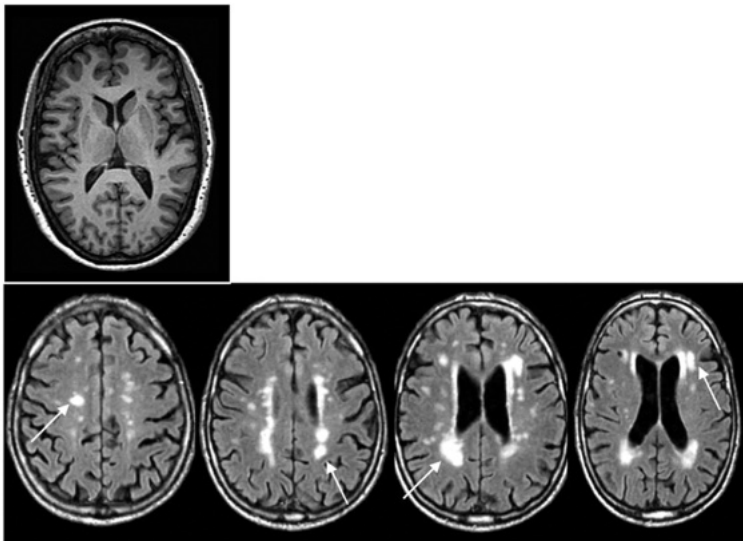
Tumors

- A tumor, or neoplasm, is a mass of tissue that grows abnormally and has no physiological function.
- Glial cells and other supporting white matter tissues.
- Benign (良性的) vs Malignant or cancerous (恶性的)
- Brain tumor: location, prognosis

Degenerative and Infectious Disorders

Disorder	Type	Most common Pathology
Alzheimer's disease	Degenerative	Tangles (结节) and plaques (斑块) in limbic and temporoparietal cortex
Parkinson's disease	Degenerative	Loss of dopaminergic neurons (多巴胺神经元)
Huntington's disease	Degenerative	Atrophy (萎缩) of interneurons in caudate and putamen nuclei of basal ganglia
Pick's disease (匹克氏病)	Degenerative	Fronto-temporal atrophy (萎缩)
Progressive supranuclear palsy (PSP) (进行性核上性麻痹)	Degenerative	Atrophy of brainstem, including colliculus (丘)
Multiple sclerosis (多发性硬化)	Possibly infectious	Demyelination (髓鞘脱失), especially of fibers near ventricles
AIDS dementia (痴呆)	Viral infection	Diffuse white matter lesions
Herpes simplex (单纯性疱疹)	Viral infection	Destruction of neurons in temporal and limbic regions
Korsakoff's syndrome (健忘综合征)	Nutritional deficiency	Destruction of neurons in diencephalon and temporal lobes

A MRI image of Alzheimer's disease



Traumatic Brain Injury

- Traumatic Brain Injury (外伤性脑损伤) can result from either a closed or an open head injury

Epilepsy

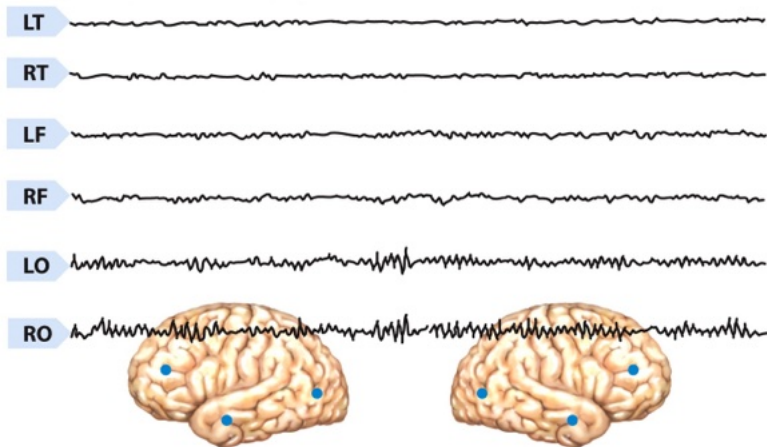
Epilepsy

- Epilepsy (癲癇) is a condition characterized by excessive and abnormally patterned activity in the brain.

Epilepsy

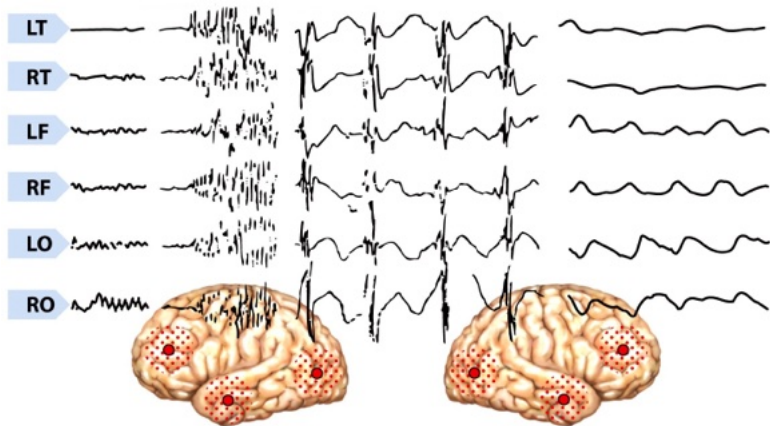
- Epilepsy (癲癇) is a condition characterized by excessive and abnormally patterned activity in the brain.
- Although 0.5% of the general population has epilepsy, it is estimated that 5% of people will have a seizure at some point during life, usually triggered by an acute event such as trauma, exposure to toxic chemicals, or high fever.

Epilepsy and electroencephalography



(Chappell et al., 2006)

Epilepsy and electroencephalography



(Chappell et al., 2006)

Functional Neurosurgery

Functional Neurosurgery

- Functional Neurosurgery (功能性神经外科):
Intervention to Alter or Restore Brain Function.

Functional Neurosurgery

- Functional Neurosurgery (功能性神经外科):
Intervention to Alter or Restore Brain Function.
- Epilepsy and Callosotomy (胼胝体离断术):
Split-brain procedure;

Functional Neurosurgery

- Functional Neurosurgery (功能性神经外科):
Intervention to Alter or Restore Brain Function.
- Epilepsy and Callosotomy (胼胝体离断术):
Split-brain procedure;
- Parkinson's disease and Deep-brain stimulation (DBS)
(深部脑刺激):
Electrodes are implanted in the basal ganglia.

Studying the Damaged Brain

Neurological dysfunction and Language deficits

Language deficits

Language deficits

- Aphasia (失语症): A broad term referring to the collective deficits in language comprehension and production that accompany neurological damage, even though the articulatory mechanisms are intact.

Language deficits

- Aphasia (失语症): A broad term referring to the collective deficits in language comprehension and production that accompany neurological damage, even though the articulatory mechanisms are intact.
 - ▶ Extremely common following brain damage

Language deficits

- Aphasia (失语症): A broad term referring to the collective deficits in language comprehension and production that accompany neurological damage, even though the articulatory mechanisms are intact.
 - ▶ Extremely common following brain damage
 - ▶ Approximately 40% of all strokes produce some aphasia

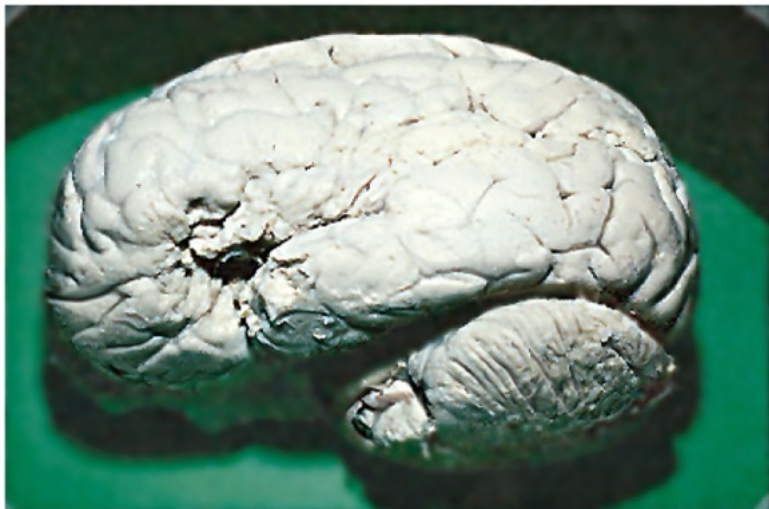Language deficits

- Aphasia (失语症): A broad term referring to the collective deficits in language comprehension and production that accompany neurological damage, even though the articulatory mechanisms are intact.
 - ▶ Extremely common following brain damage
 - ▶ Approximately 40% of all strokes produce some aphasia
- Speech apraxia (语言失用): Deficits in the motor planning of articulations.

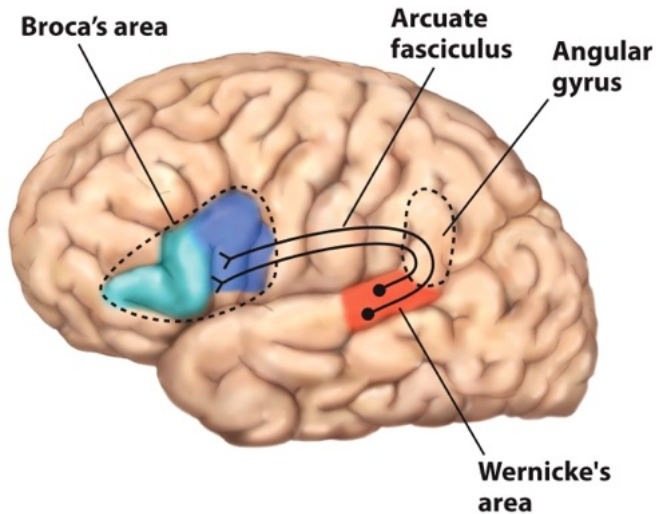
Language deficits

- Aphasia (失语症): A broad term referring to the collective deficits in language comprehension and production that accompany neurological damage, even though the articulatory mechanisms are intact.
 - ▶ Extremely common following brain damage
 - ▶ Approximately 40% of all strokes produce some aphasia
- Speech apraxia (语言失用): Deficits in the motor planning of articulations.
- Dysarthria (构音障碍): Caused by the loss of control over articulatory muscles.

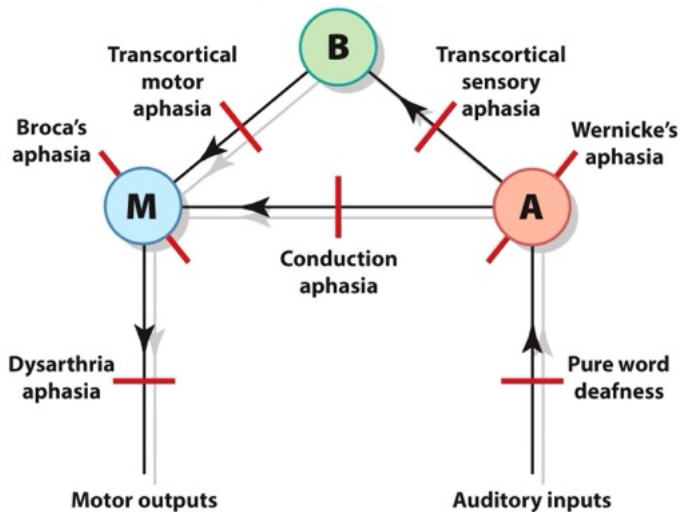
Lateral view of the brain of Leborgne



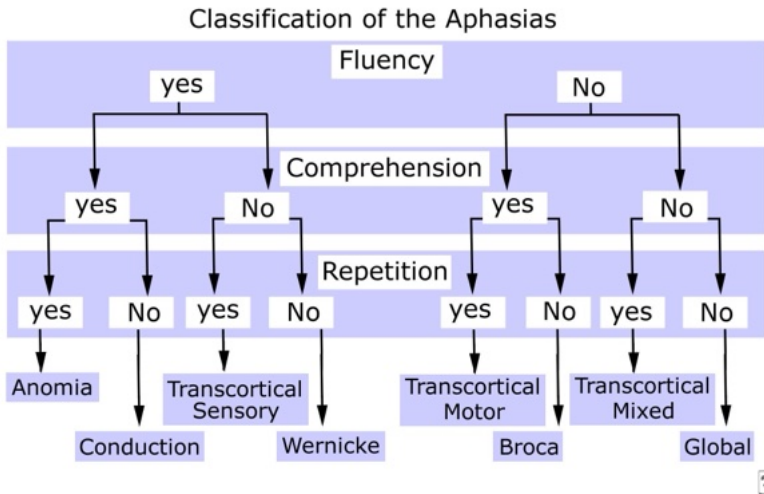
Broca's area and Wernicke's area



Lichtheim's model of language processing



Summary of Cortical Aphasias

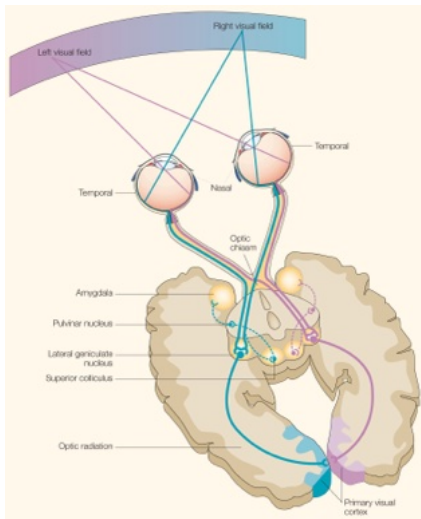


<https://emedicine.medscape.com/article/317758-overview>

Studying the Damaged Brain

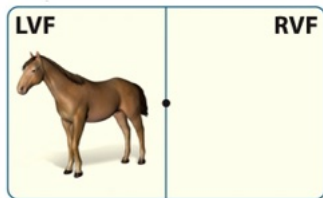
Functional neurosurgery and language disorders

Information projecting into two hemispheres



Object naming

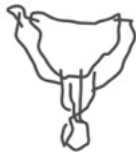Visual stimulus



Examiner: "What was it?" "What goes on it?"

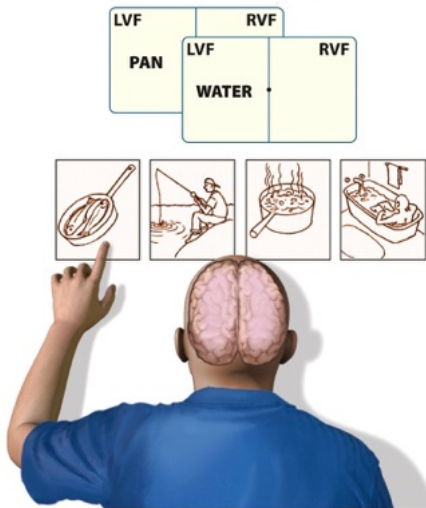
Verbal response: "I don't know." "I don't know."

**Left-hand drawing:
(saddle)**




(Gazzaniga et al., 2014, p.138)

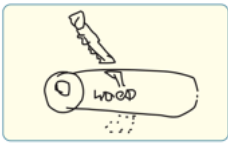
Make inference




(Gazzaniga et al., 2014, p.138)

Information integration

a 

b 

c 

LVF - RVF

Toad - Stool


Toadstool: 伞菌

See - Saw

Scraper - Sky

(Gazzaniga et al., 2014, p.142)

Information integration

a 

b 

c 

LVF - RVF

Toad - Stool

Toadstool: 伞菌

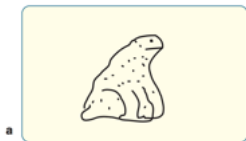See - Saw

Seesaw: 跷跷板

Scraper - Sky

(Gazzaniga et al., 2014, p.142)

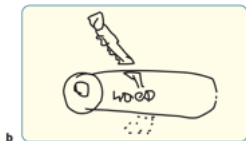Information integration



LVF - RVF

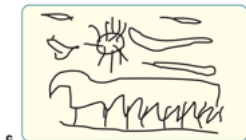Toad - Stool

Toadstool: 伞菌



See - Saw

Seesaw: 跷跷板

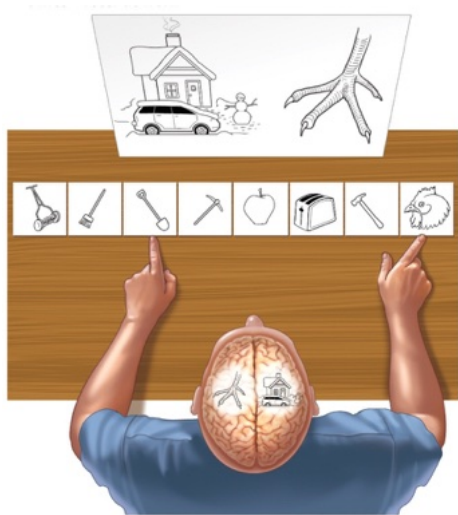


Scraper - Sky

Skyscraper: 摩天大楼

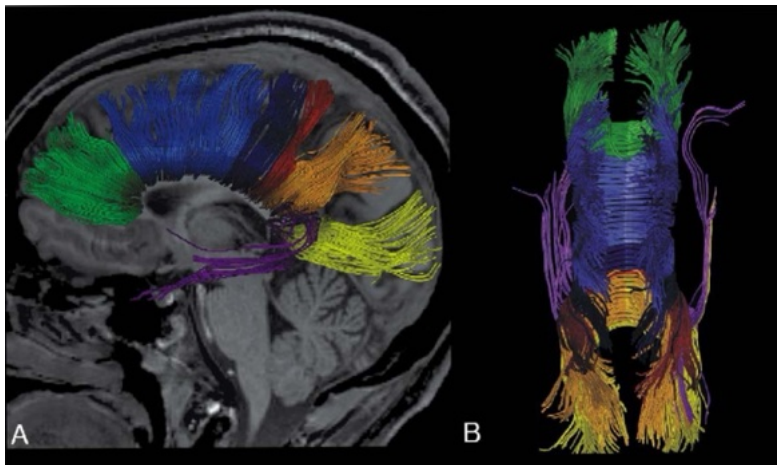
(Gazzaniga et al., 2014, p.142)

The interpreter



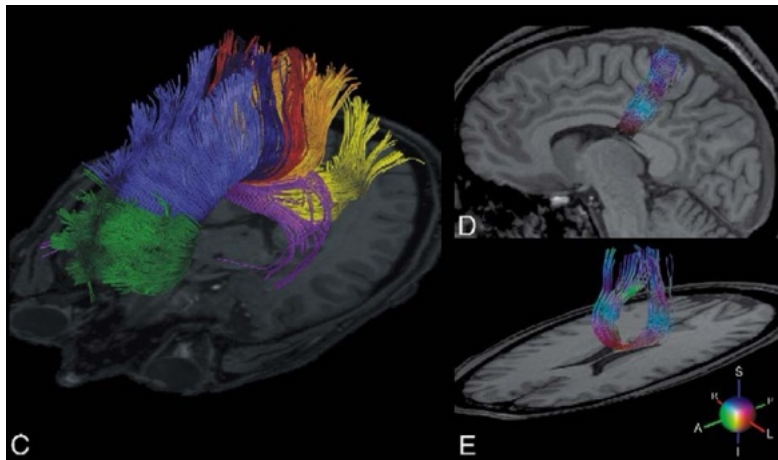
(Gazzaniga et al., 2014, p.147)

Callosal projection



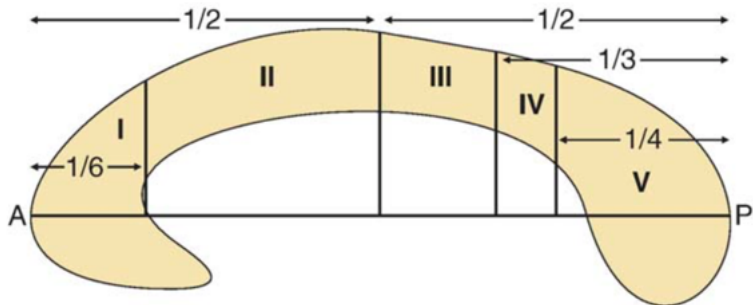
(Hofer & Frahm, 2006)

Callosal projection



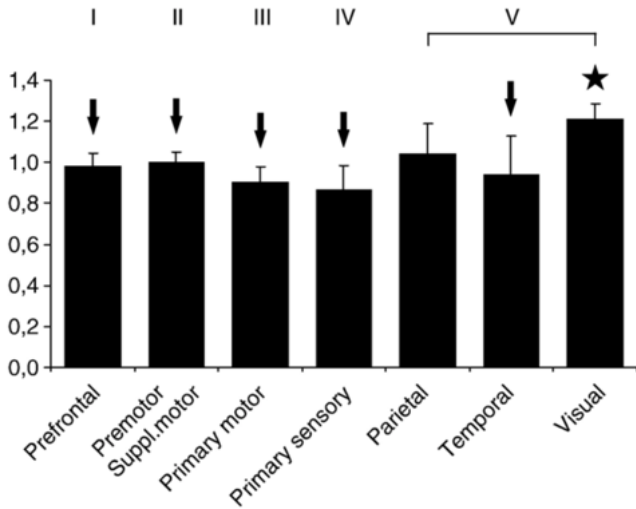
(Hofer & Frahm, 2006)

Callosal projection



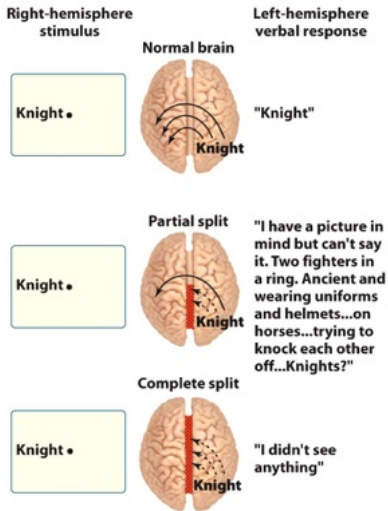
(Hofer & Frahm, 2006)

Callosal projection



(Hofer & Frahm, 2006)

Callosal Function Specificity



Perturbing Neural Function

Perturb Neural Function

Perturb Neural Function

- Pharmacology (药理学)

Perturb Neural Function

- Pharmacology (药理学)
- Transcranial Magnetic Stimulation (TMS, 经颅磁刺激)

Perturb Neural Function

- Pharmacology (药理学)
- Transcranial Magnetic Stimulation (TMS, 经颅磁刺激)
- Transcranial Direct Current Stimulation (tDCS, 经颅直流电刺激)

Perturb Neural Function

- Pharmacology (药理学)
- Transcranial Magnetic Stimulation (TMS, 经颅磁刺激)
- Transcranial Direct Current Stimulation (tDCS, 经颅直流电刺激)
- Genetic manipulation (基因控制)

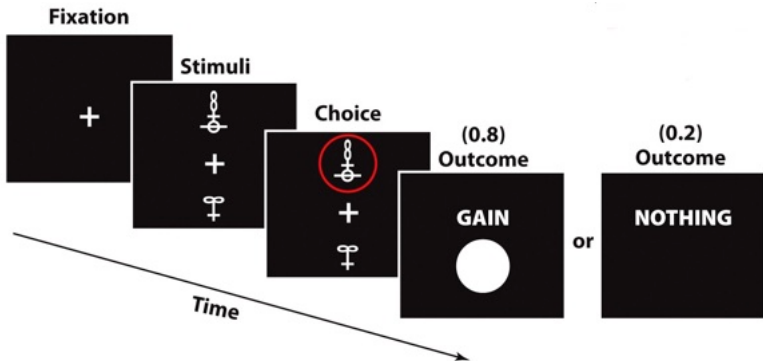
Perturb Neural Function

- Pharmacology (药理学)
- Transcranial Magnetic Stimulation (TMS, 经颅磁刺激)
- Transcranial Direct Current Stimulation (tDCS, 经颅直流电刺激)
- Genetic manipulation (基因控制)
 - ▶ Knockout gene (基因敲除)

Perturb Neural Function

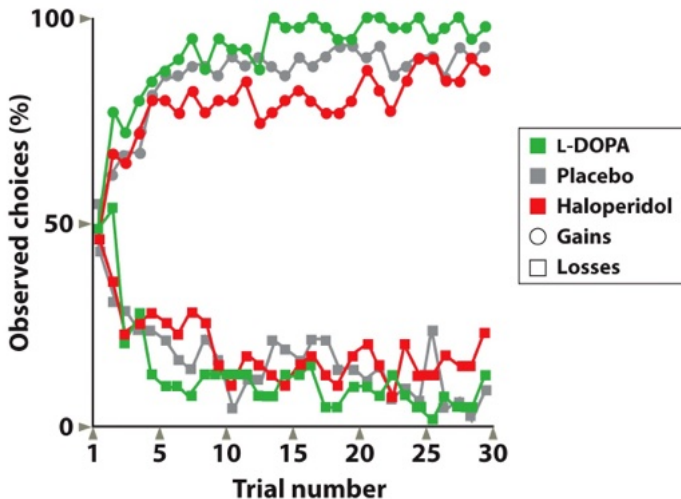
- Pharmacology (药理学)
- Transcranial Magnetic Stimulation (TMS, 经颅磁刺激)
- Transcranial Direct Current Stimulation (tDCS, 经颅直流电刺激)
- Genetic manipulation (基因控制)
 - ▶ Knockout gene (基因敲除)
 - ▶ Optogenetics (光遗传学)

Pharmacology



(Pessiglione, Seymour, Flandin, Dolan, & Frith, 2006)

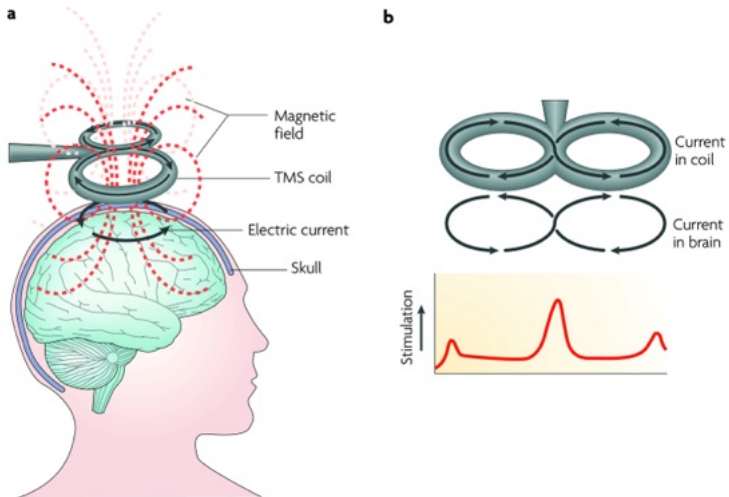
Pharmacology



Transcranial Magnetic Stimulation



Transcranial Magnetic Stimulation

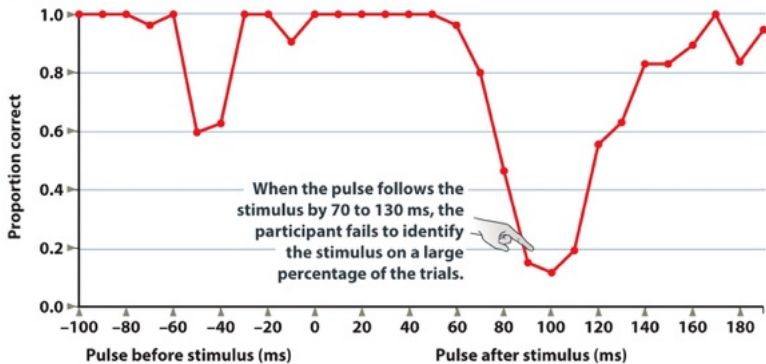


Occipital lobe and letter identification

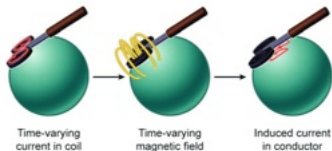
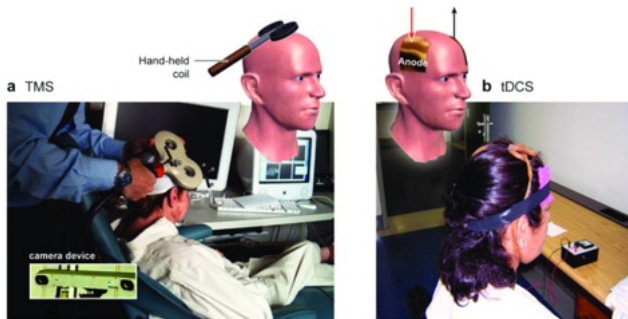
Transcranial magnetic stimulation over the occipital lobe



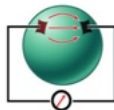
Occipital lobe and letter identification



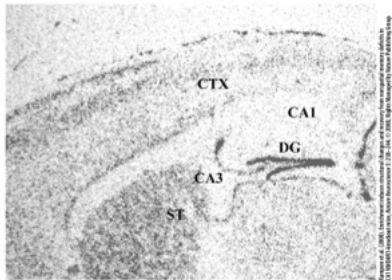
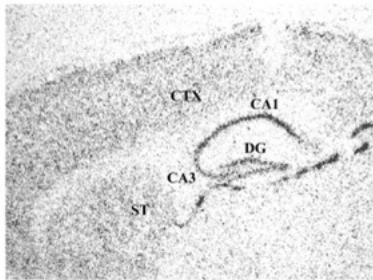
Transcranial Direct Current Stimulation



DC current applied via pair of electrodes; current induced in conductor

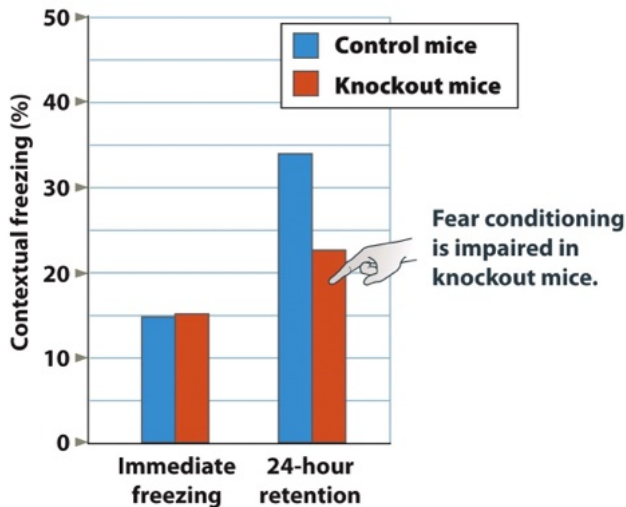


Gene knockout

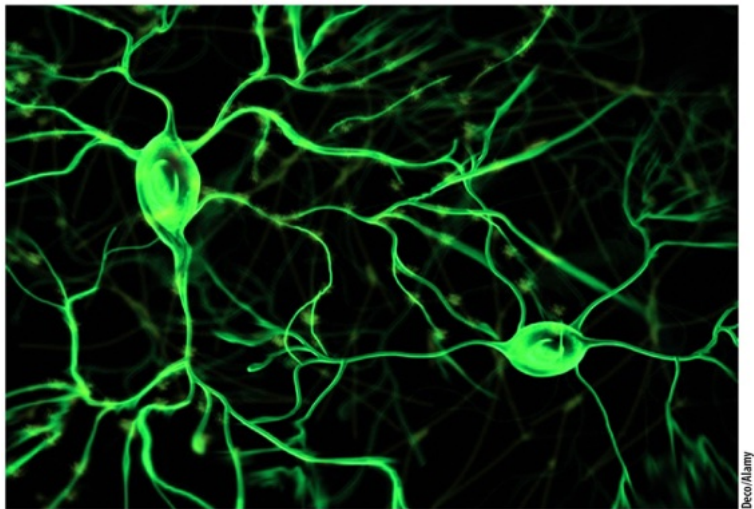


(Rampon et al., 2000)

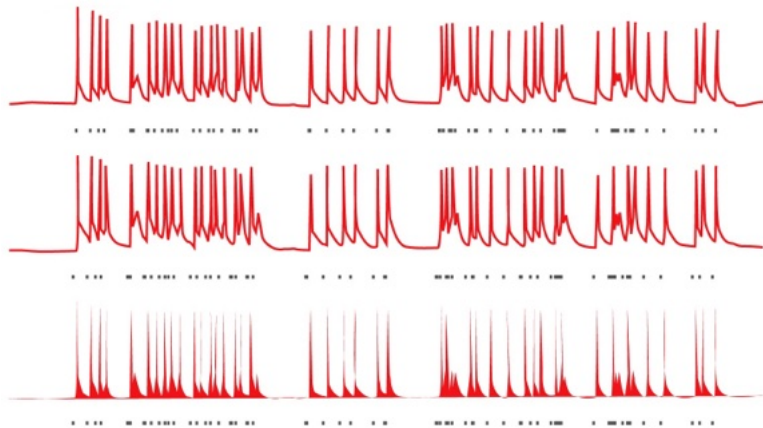
Gene knockout



Optogenetics




Optogenetics



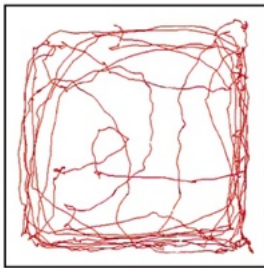
(Tye et al., 2011)

Optogenetics

Off



On



(Tye et al., 2011)

Studying Neural function


Studying Neural function

- Single-Cell Recording
- Magnetoencephalography (MEG, 脑磁图仪)
- Scalp Electroencephalography (EEG, 脑电仪)
- Intracranial electroencephalography (iEEG) or Electrocortogram (ECoG, 皮层下脑电)

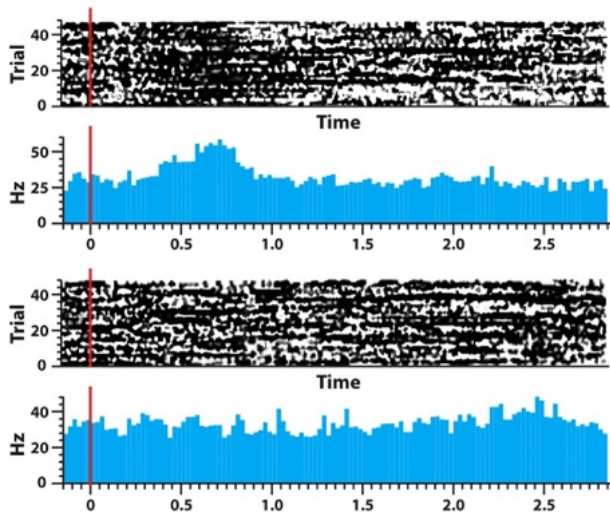
Studying Neural function

Single-Cell Recording

Neural signals

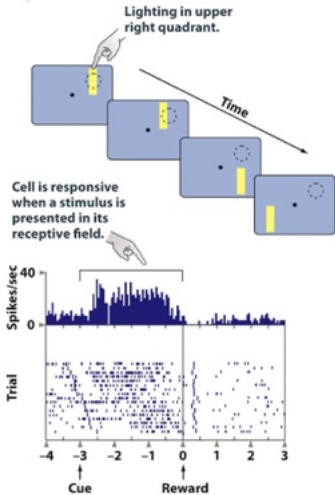
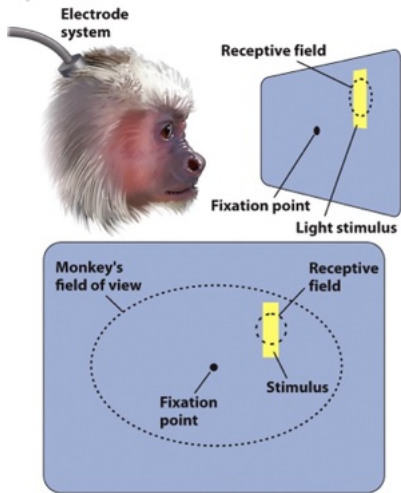


Raster plots (光栅图)



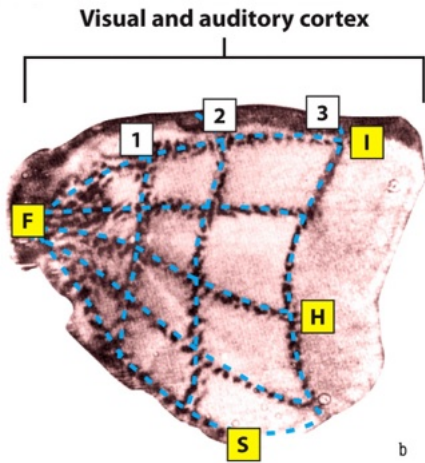
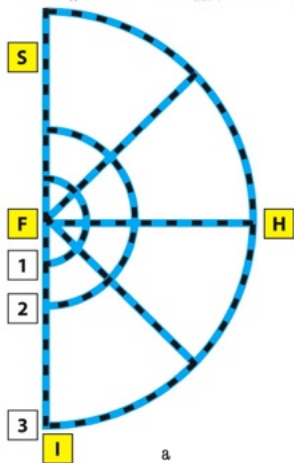
(Gonzalez Andino & Grave de Peralta Menendez, 2012)

Single-Cell Recordings in Animals



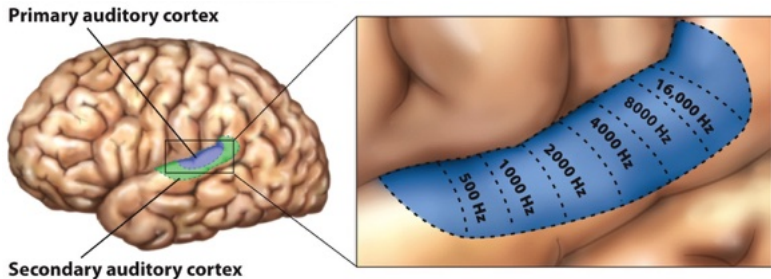
(Mori & Zhang, 2006)

Retinotopic map



(Gazzaniga et al., 2014, p.98)

Tonotopic or Cochleotopic maps

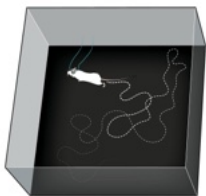
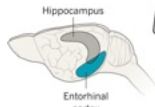


(Gazzaniga et al., 2014, p.98)

Place cells

A SENSE OF PLACE

Edvard and May-Britt Moser study grid cells in the brain's entorhinal cortex that help animals to understand where they are.



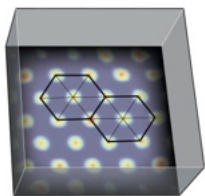
RAT ON THE RUN

The Mosers insert electrodes into a rat's entorhinal cortex and measure electrical signals from individual grid cells as the rat runs around a box, eating chocolate treats.



FIRING PATTERN

A single grid cell fires when a rat crosses certain points on the floor; it turns out that these points form a hexagonal grid, like a honeycomb.



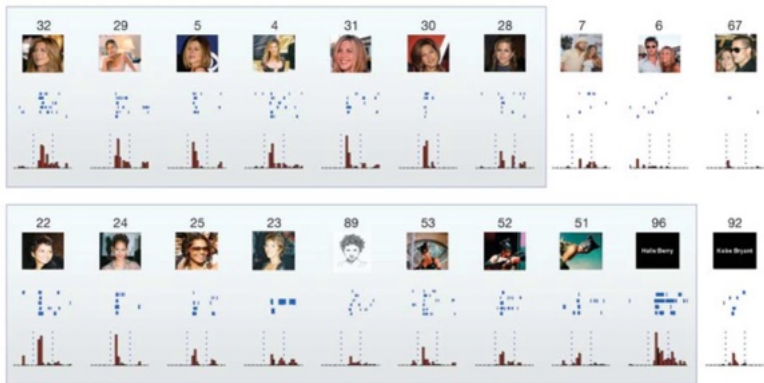
POSITIONING SYSTEM

A hexagonal pattern gives the highest-possible spatial resolution with the fewest cells. Each cell generates its own grid, and these overlapped patterns help the animal to recognize its location and direction.

(Abbott, 2014)

The Nobel Prize in Physiology or Medicine 2014 was divided, one half awarded to John O'Keefe, the other half jointly to May-Britt Moser and Edvard I. Moser
“for their discoveries of cells that constitute a positioning system in the brain”.

Single-Cell Recordings in human



(Quiroga, Reddy, Kreiman, Koch, & Fried, 2005)

Studying Neural function

MEEG

EEG and MEG

EEG and MEG

- 脑电仪是记录大脑中生物电信号的脑成像技术。

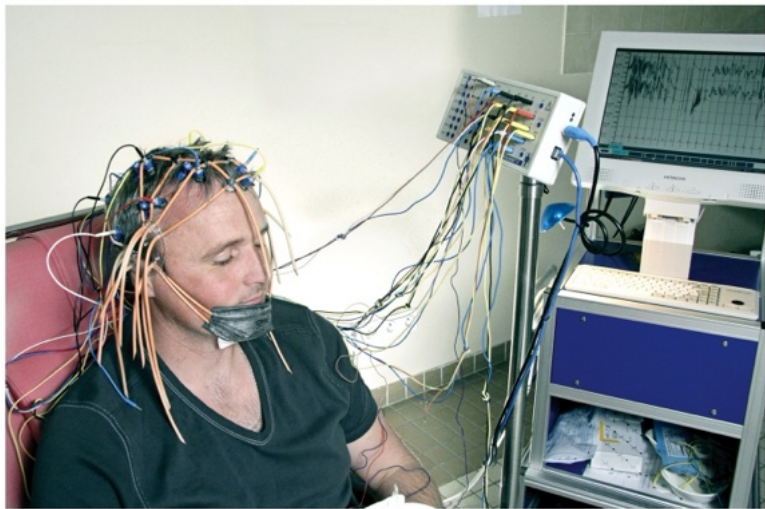Electro Encelphalo Graphy (EEG)

电 脑 图

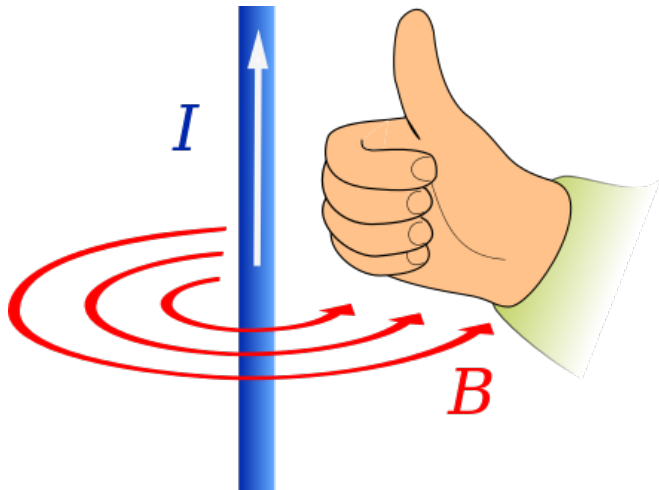
EEG and MEG

- 脑电仪是记录大脑中生物电信号的脑成像技术。
Electro Encelphalo Graphy (EEG)
电 脑 图
- 脑磁图仪是记录大脑中生物磁信号的脑成像技术。
Magneto Encelphalo Graphy (MEG)
磁 脑 图

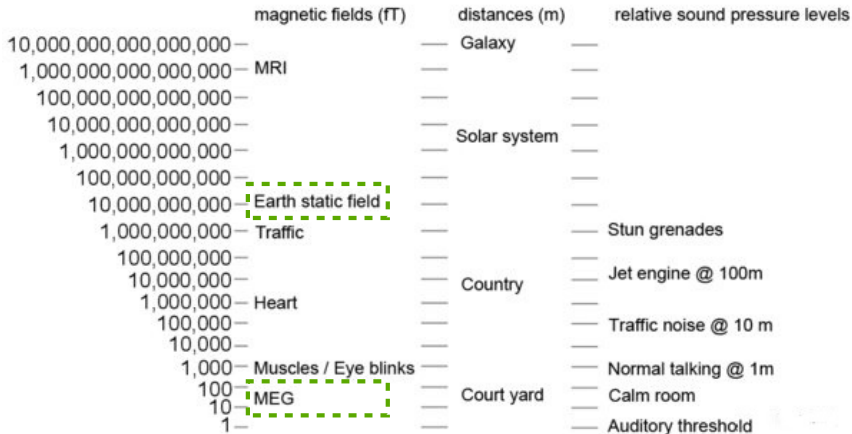
Electroencephalography




Bioelectric and biomagnetic signals



Biomagnetic signals are tiny



Magnetically shielded room



SQUIDS

Superconducting Quantum Interference Device (SQUIDS)

SQUIDS

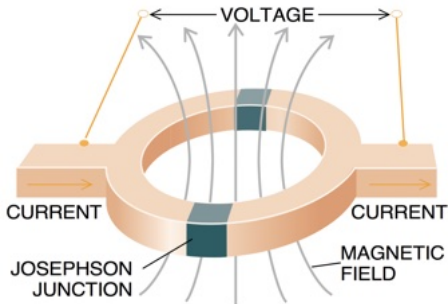
Superconducting Quantum Interference Device (SQUIDS)

超导 量子 干涉 仪

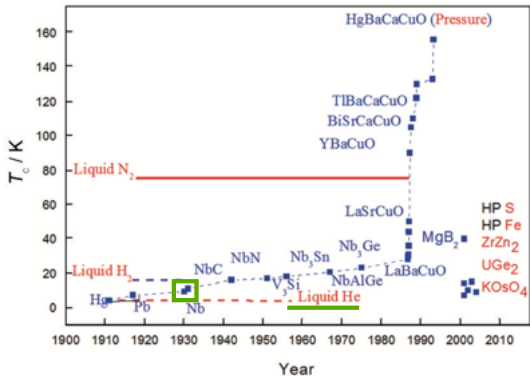
SQUIDS

Superconducting Quantum Interference Device (SQUIDS)

超导 量子 干涉 仪



Superconductors




- 铌临界温度 (Niobium, Nb): -263 摄氏度
- 液氦沸点 (Liquid Helium, LHe): -269 摄氏度

Dewar and Boat in a bottle

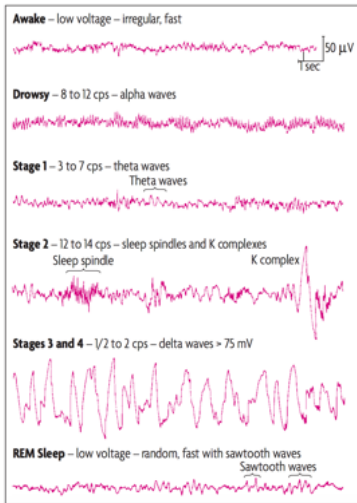


全脑磁束计

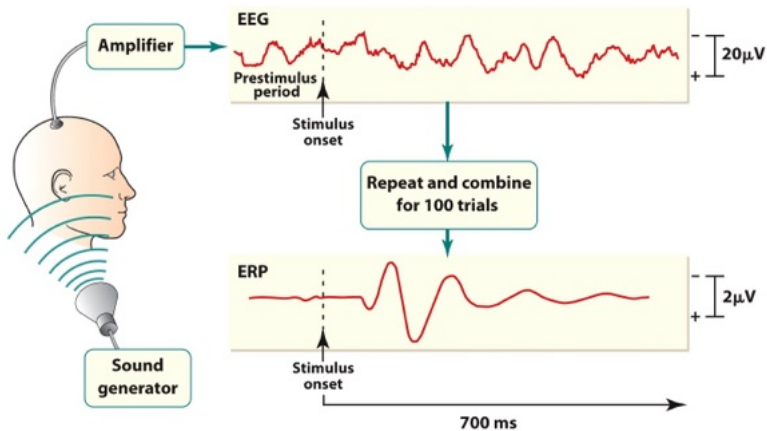


杜瓦罐形状

EEG profiles at different states of consciousness

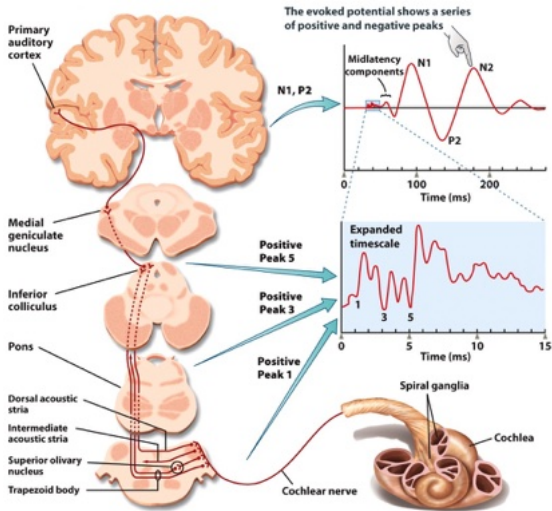


Event-related potentials



(Gazzaniga et al., 2014, p.100)

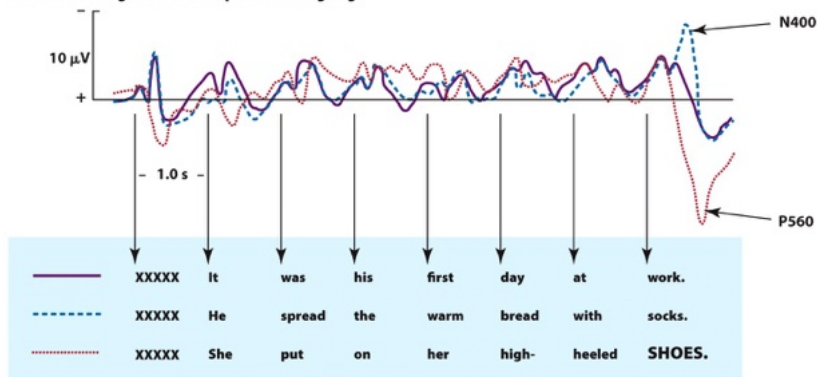
Auditory evoked potentials (AERs)



(Quiroga et al., 2005)

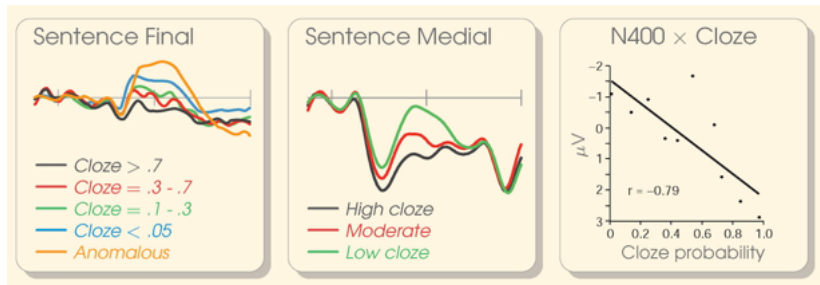
Semantic Processing and the N400 Wave

ERPs reflecting semantic aspects of language



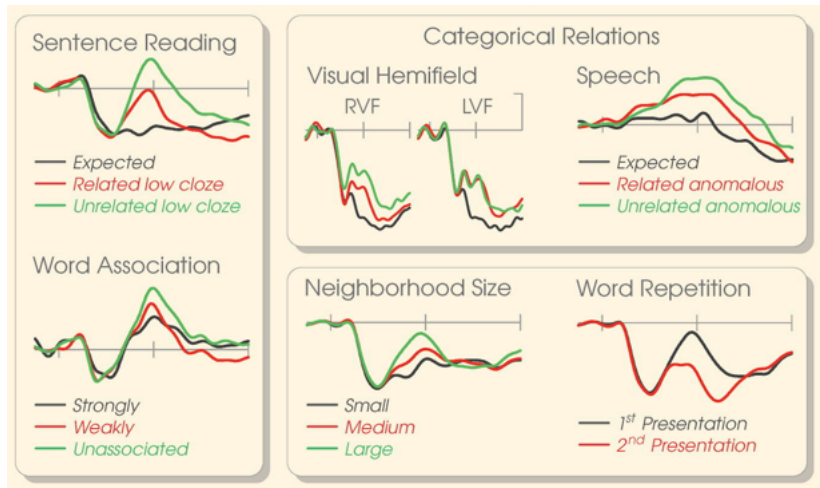
(Kutas & Hillyard, 1980)

Semantic Processing and the N400 Wave



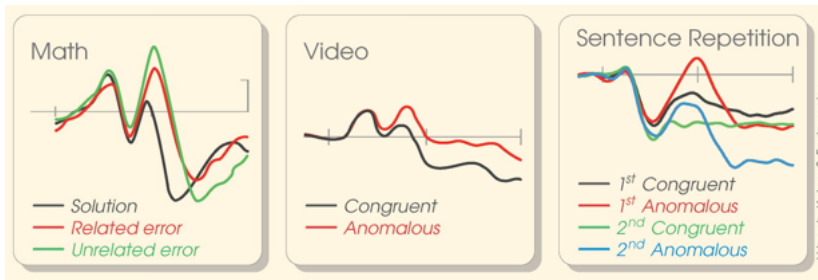
(Kutas & Federmeier, 2011)

Semantic Processing and the N400 Wave



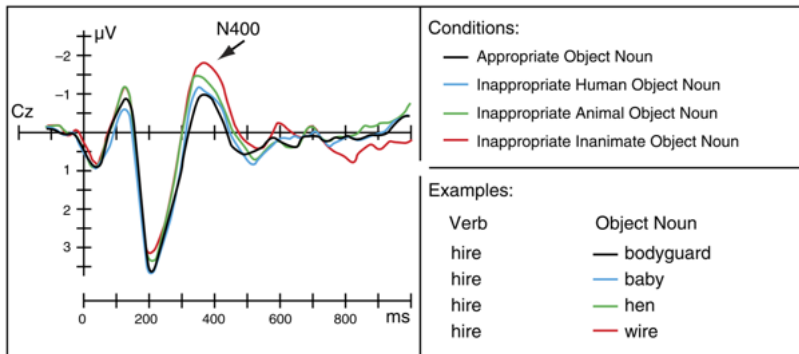
(Kutas & Federmeier, 2011)

Semantic Processing and the N400 Wave



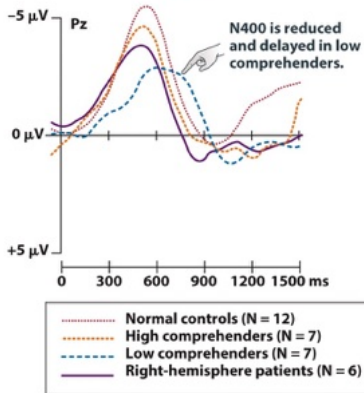
(Kutas & Federmeier, 2011)

Semantic Processing and the N400 Wave



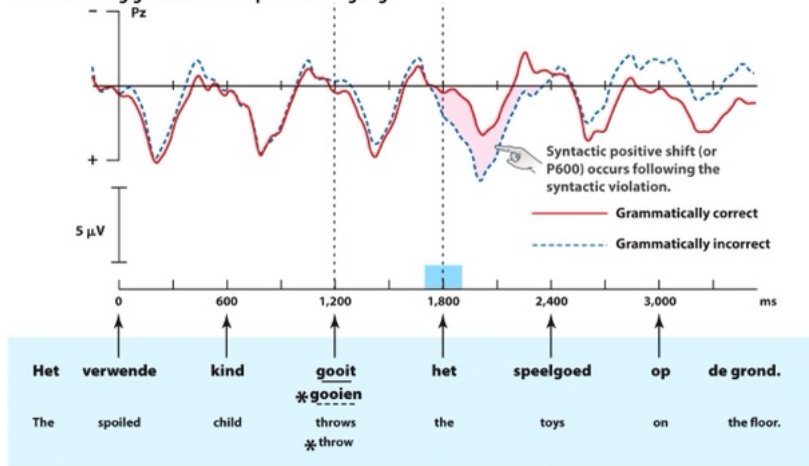
(Friederici, 2011)

Semantic Processing and the N400 Wave



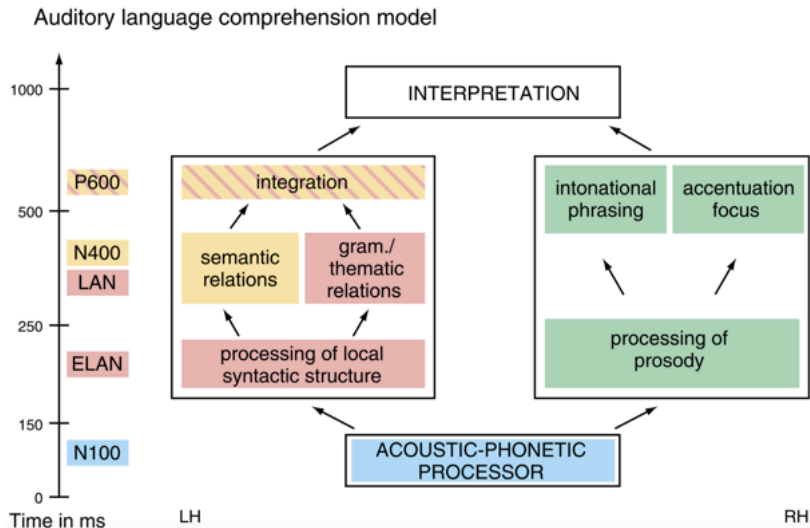
Syntactic Processing and the P600 Wave

ERPs reflecting grammatical aspects of language

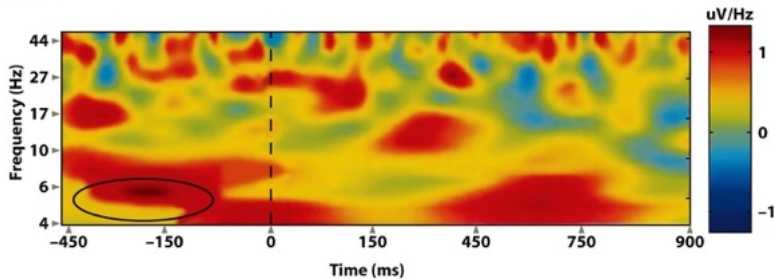


(Hagoort, Brown, & Groothusen, 1993)

Semantic Processing and the N400 Wave



Time-frequency analysis

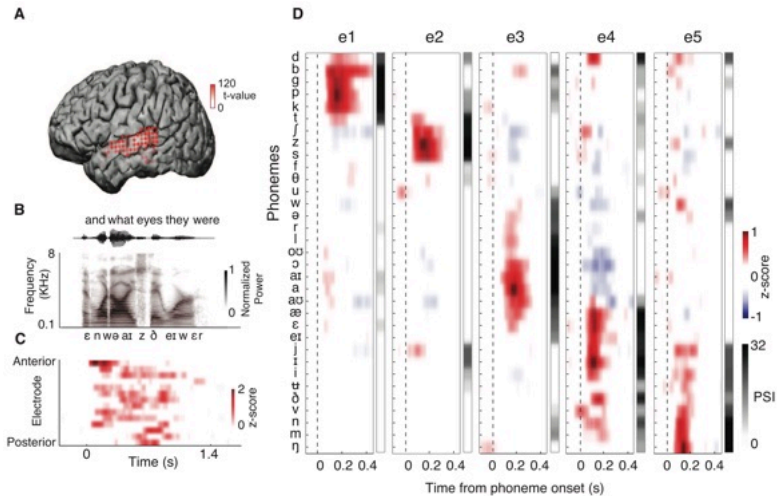


(Addante, Watrous, Yonelinas, Ekstrom, & Ranganath, 2011)

Studying Neural function

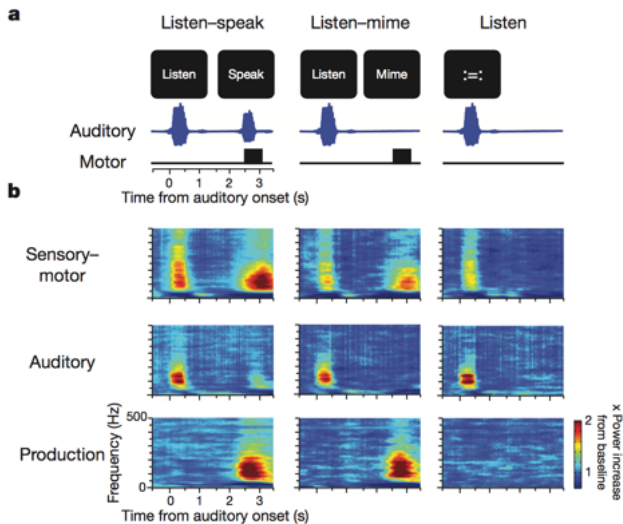
Electrocortogram

Electrocortogram



(Mesgarani, Cheung, Johnson, & Chang, 2014)

Electrocortogram



The complexity of neural signals

- 一个神经元可以有高达 1.5×10^4 个突触连接；
- 大脑皮层共包含约 2×10^{10} 个神经元细胞；
- 大脑皮层总共约有 2.4×10^{14} 个突触连接；
- 大脑皮层面积约 2.5×10^5 平方毫米；
- 每平方毫米大约有 10^5 个神经元和 10^9 个突触连接；

Analyzing the Brain Structure

Structural Analysis of the Brain

Structural Analysis of the Brain

- Computed Tomography (CT, 计算机断层扫描)

Structural Analysis of the Brain

- Computed Tomography (CT, 计算机断层扫描)
- Magnetic Resonance Imaging (MRI, 磁共振成像)

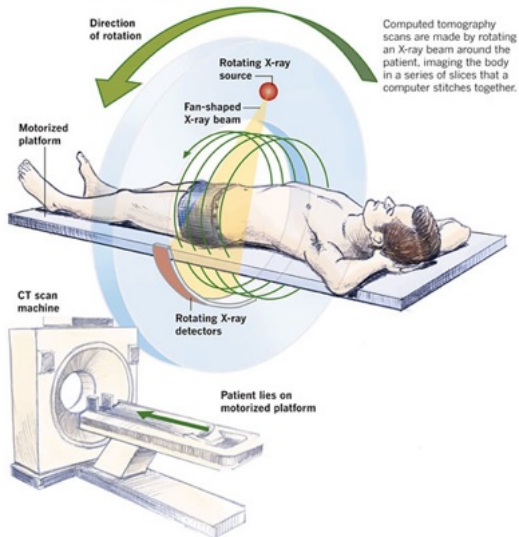
Structural Analysis of the Brain

- Computed Tomography (CT, 计算机断层扫描)
- Magnetic Resonance Imaging (MRI, 磁共振成像)
- Diffusion Tensor Imaging (DTI, 扩散张量成像)

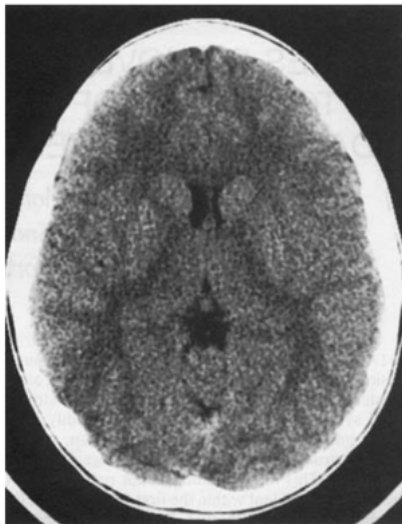
Analyzing the Brain Structure

Computed tomography (CT)

Computed tomography (CT)



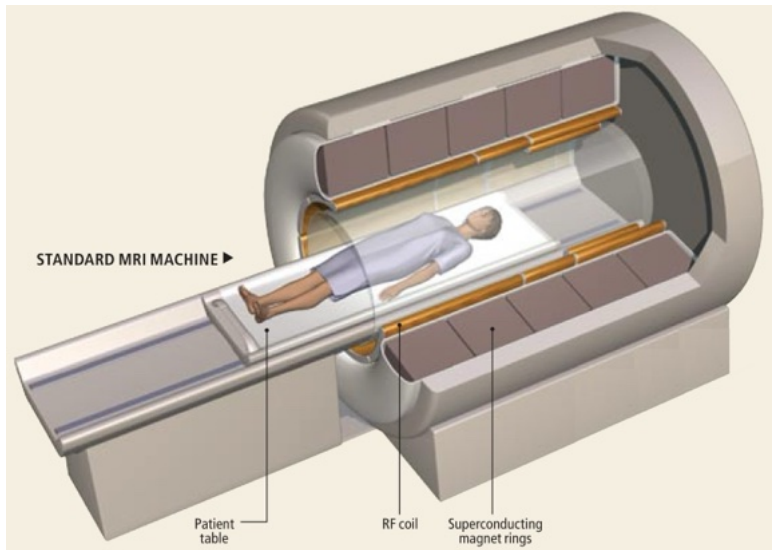
Computed tomography (CT)



Analyzing the Brain Structure

Magnetic Resonance Imaging

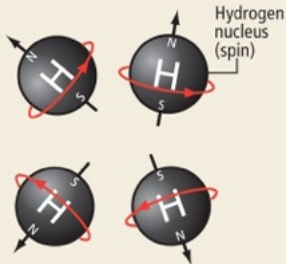
Magnetic Resonance Imaging



Magnetic Resonance Imaging

Creation of Nuclear Magnetization

1 RANDOM ORIENTATION



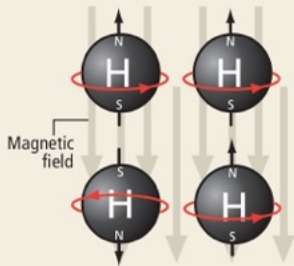
Single, unpaired protons (here, hydrogen nuclei) spin on their axes along random orientations. The motion of the positively charged protons (known as spins) makes them act as if they are tiny bar magnets.

(Blümich, 2008)

Magnetic Resonance Imaging

Creation of Nuclear Magnetization

2 MAGNETIZED SPINS ALIGN...



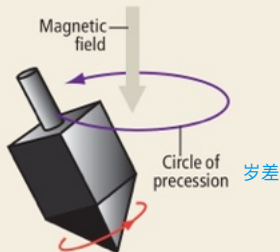
When the NMR machine applies a strong magnetic field to the sample, the spins (on average) tend to align their axes along the field lines.

(Blümich, 2008)

Magnetic Resonance Imaging

Creation of Nuclear Magnetization

3 ... AND PRECESS LIKE TOPS



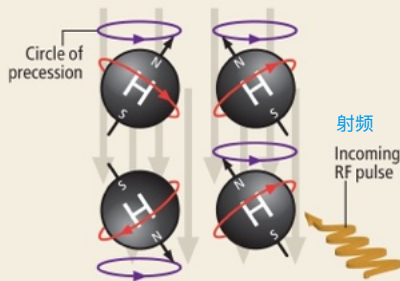
The alignment is inexact, though, resulting in precession—the axes rotate around the field lines—at a frequency that is unique for each type of nucleus and chemical group in a molecule.

(Blümich, 2008)

Magnetic Resonance Imaging

RF Energy Absorption and Release

1 MAGNETIZED SPIN GROUP



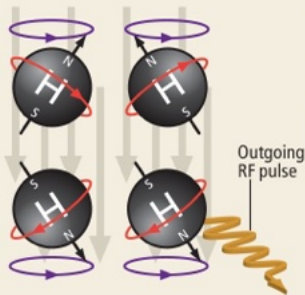
Magnetized spins precess along random orientations in the magnetic field. When a coil in the NMR machine sends an RF pulse toward the group, only a spin that precesses at a rate and phase that matches the pulse's frequency can absorb its energy.

(Blümich, 2008)

Magnetic Resonance Imaging

RF Energy Absorption and Release

2 SPIN HAS ABSORBED RF ENERGY



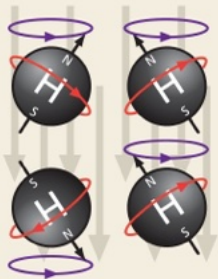
Absorption causes the spin to flip 180 degrees. All nuclei that interact with the RF pulse in the same way absorb its energy and flip 180 degrees. The machine's coil picks up the signal induced by the magnetization caused by these changes in spin precession and feeds it to a computer.

(Blümich, 2008)

Magnetic Resonance Imaging

RF Energy Absorption and Release

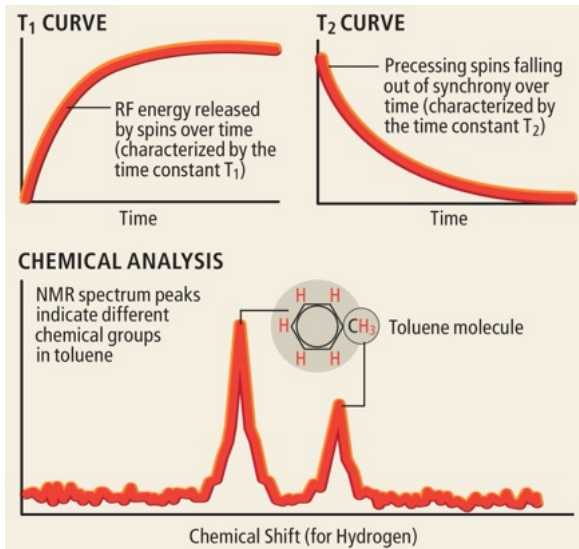
3 SPIN HAS RELEASED RF ENERGY



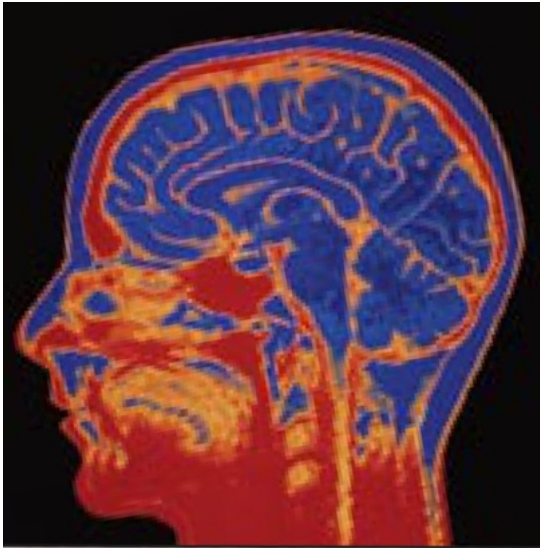
At random intervals, flipped spins release the absorbed RF energy and return to their original (prepulse) orientations.

(Blümich, 2008)

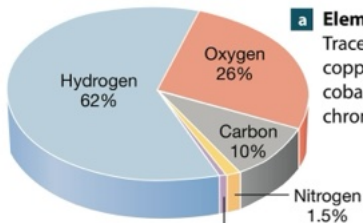
Magnetic Resonance Imaging



Magnetic Resonance Imaging



Elemental composition of the body



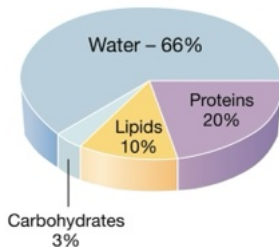
a Elemental composition of the body.

Trace elements include silicon, fluorine, copper, manganese, zinc, selenium, cobalt, molybdenum, cadmium, chromium, tin, aluminum, and boron.

OTHER ELEMENTS

Calcium	0.2%
Phosphorus	0.2%
Potassium	0.06%
Sodium	0.06%
Sulfur	0.05%
Chlorine	0.04%
Magnesium	0.03%
Iron	0.0005%
Iodine	0.0000003%
Trace elements	(see caption)

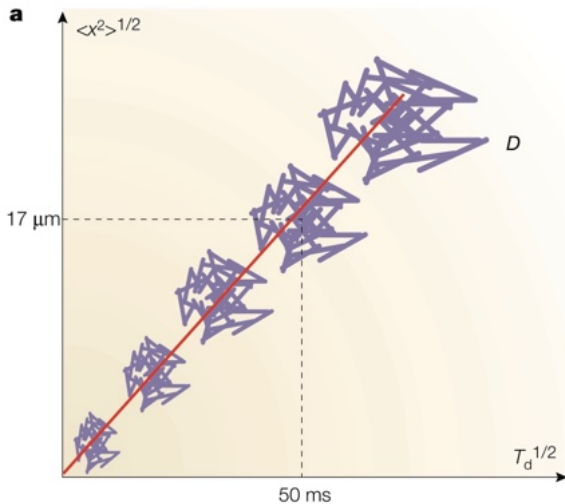
b Molecular composition of the body.



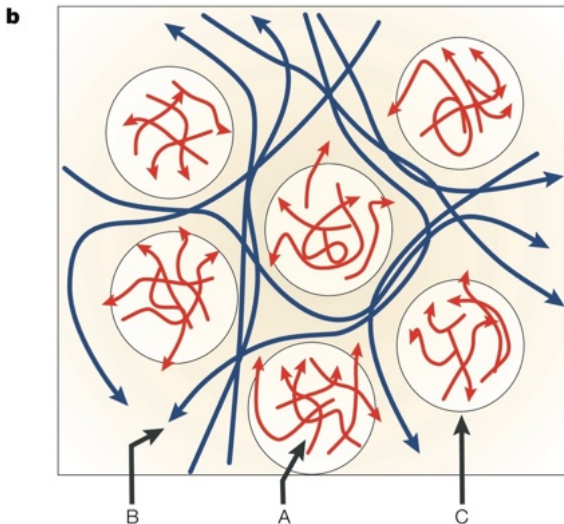
Analyzing the Brain Structure

Diffusion Tensor Imaging

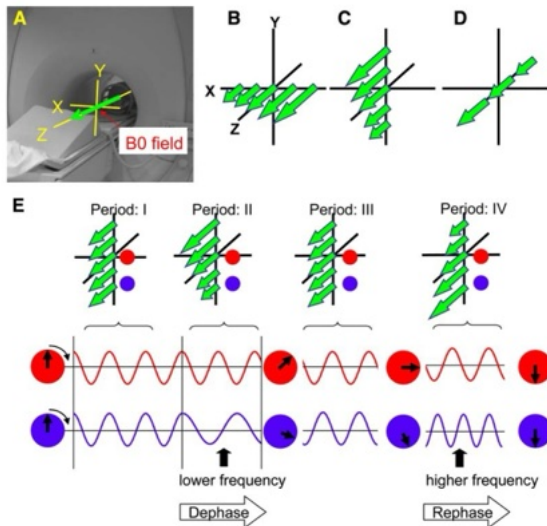
Diffusion Tensor Imaging



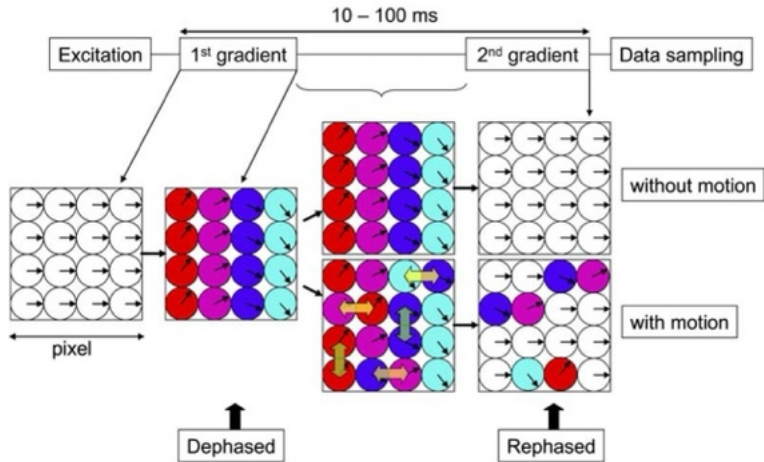
Diffusion Tensor Imaging



Diffusion Tensor Imaging

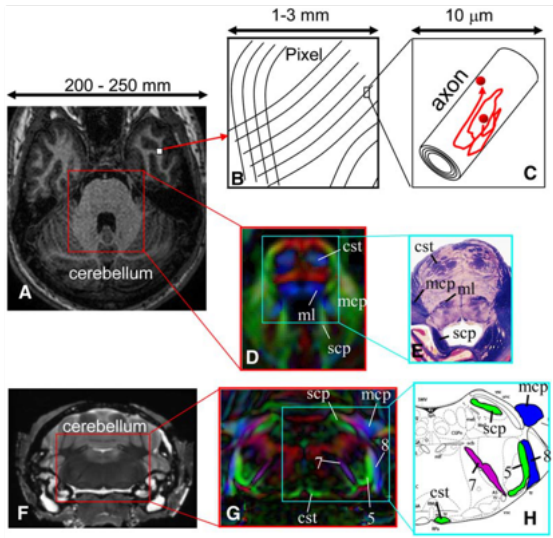


Diffusion Tensor Imaging

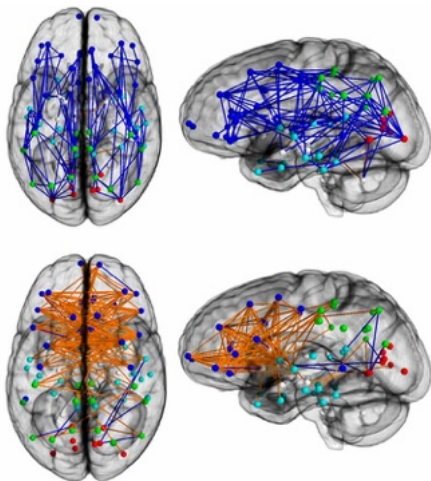


(Mori & Zhang, 2006)

Diffusion Tensor Imaging

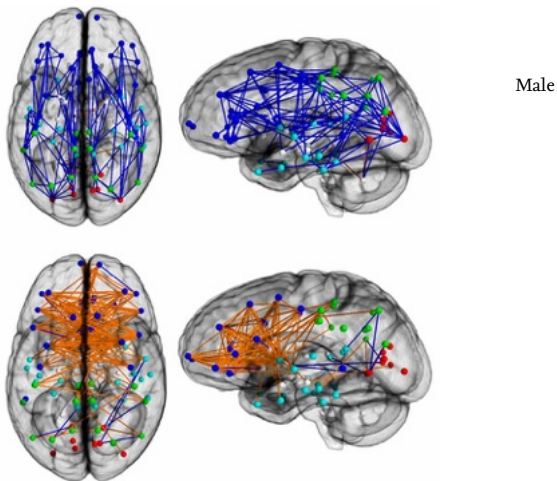


Diffusion Tensor Imaging: Sex differences



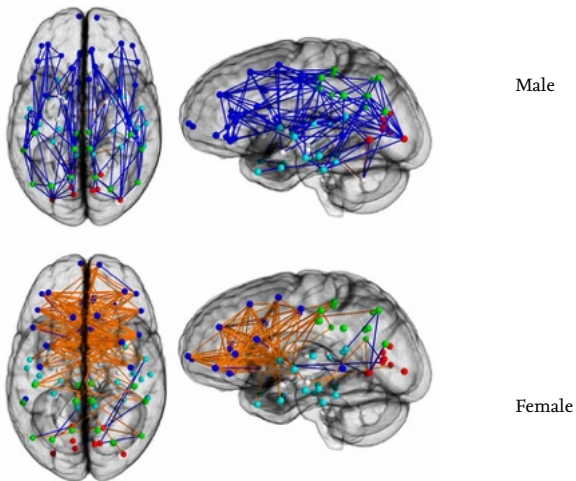
(Ingalhalikar et al., 2013)

Diffusion Tensor Imaging: Sex differences



(Ingalhalikar et al., 2013)

Diffusion Tensor Imaging: Sex differences



(Ingalhalikar et al., 2013)

Neuroimaging: Function + Structure

Neuroimaging: Function + Structure

Neuroimaging: Function + Structure

- Positron Emission Tomography
(PET, 正电子断层扫描术)

Neuroimaging: Function + Structure

- Positron Emission Tomography
(PET, 正电子断层扫描术)
- functional Magnetic Resonance Imaging
(fMRI, 功能性磁共振成像)

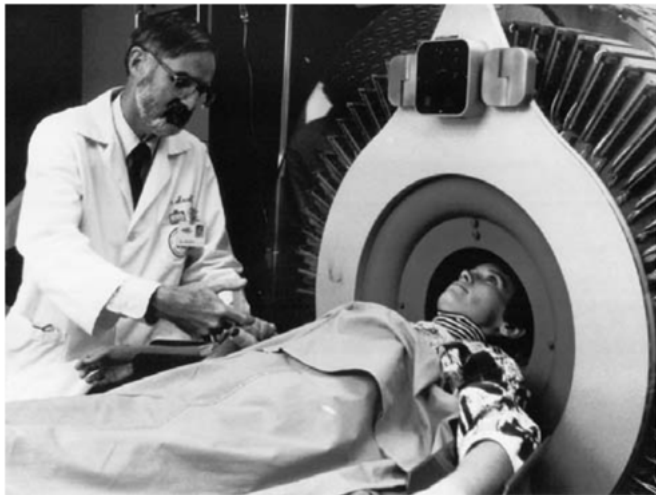Neuroimaging: Function + Structure

- Positron Emission Tomography
(PET, 正电子断层扫描术)
- functional Magnetic Resonance Imaging
(fMRI, 功能性磁共振成像)
- functional near-infrared spectroscopy
(fNIRS, 功能近红外光谱成像技术)

Neuroimaging: Function + Structure

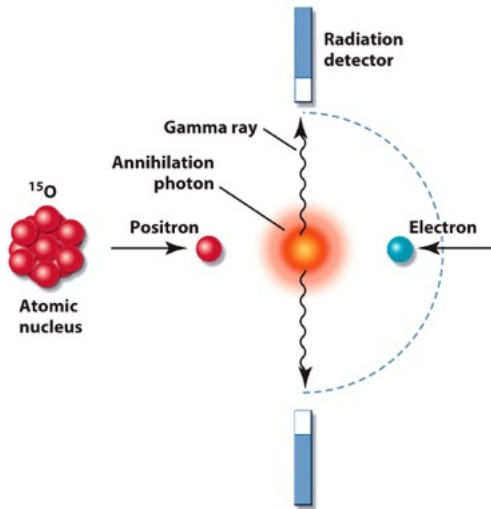
Positron Emission Tomography

Positron Emission Tomography

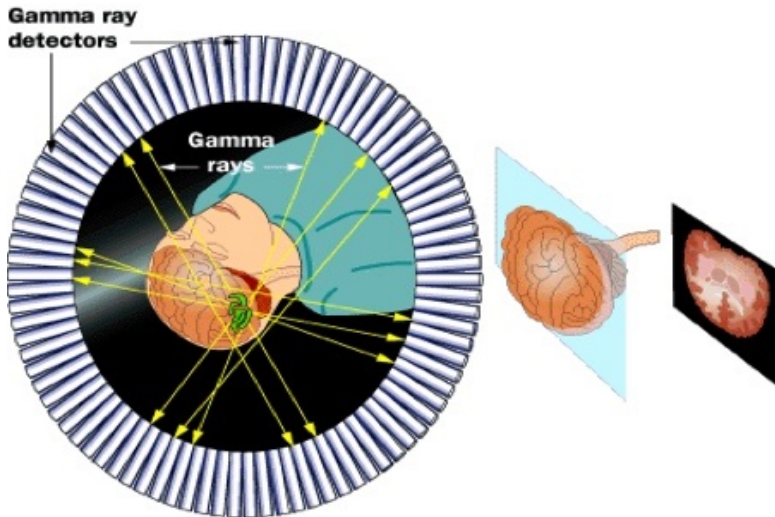


Positron Emission Tomography

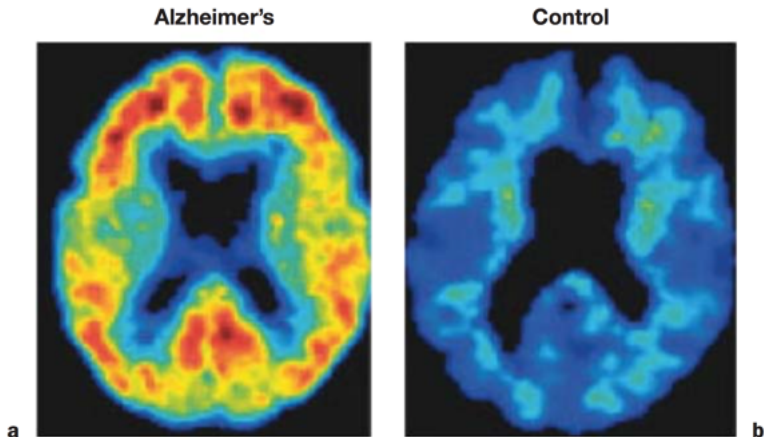
Positron Emission Tomography



Positron Emission Tomography



Using PiB to look for signs of Alzheimer's disease



(Vitali, Migliaccio, Agosta, Rosen, & Geschwind, n.d.)

Neuroimaging: Function + Structure

Functional Magnetic Resonance Imaging

BOLD signals

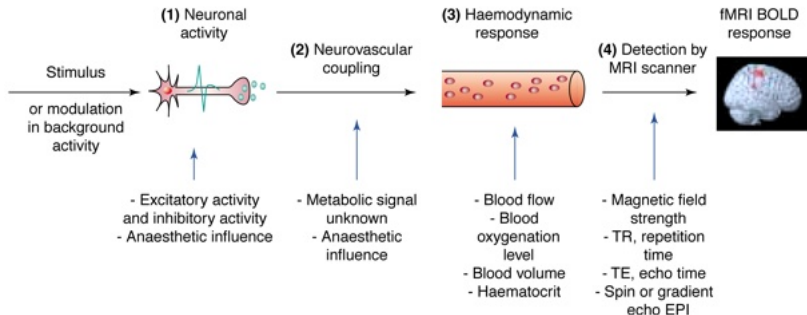
BOLD signals

- **Deoxygenated hemoglobin** (脱氧血红蛋白) is paramagnetic (i.e., weakly magnetic in the presence of a magnetic field), whereas **oxygenated hemoglobin** (含氧血红蛋白) is not.

BOLD signals

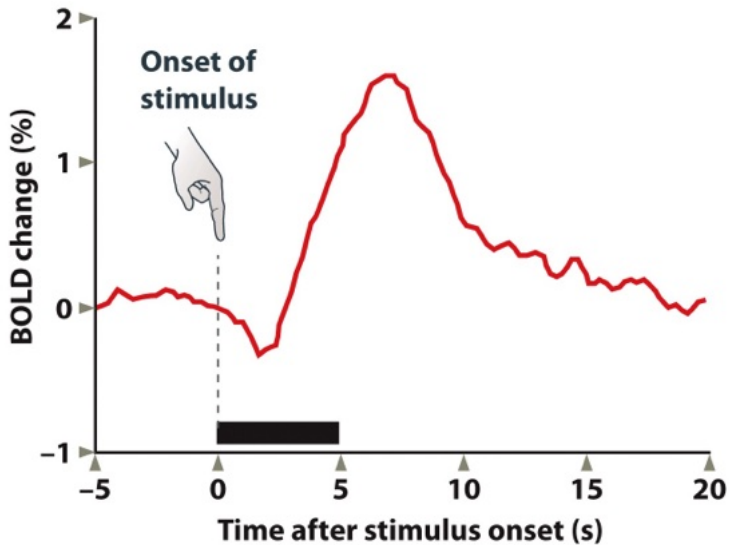
- **Deoxygenated hemoglobin** (脱氧血红蛋白) is paramagnetic (i.e., weakly magnetic in the presence of a magnetic field), whereas **oxygenated hemoglobin** (含氧血红蛋白) is not.
- fMRI detectors measure the ratio of oxygenated to deoxygenated hemoglobin; this value is referred to as the **blood oxygen level-dependent** (血氧水平依赖), or BOLD.

Functional Magnetic Resonance Imaging



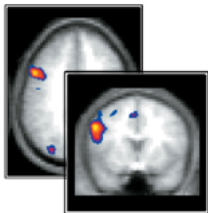
(Arthurs & Boniface, 2002)

Stimulus and BOLD signals

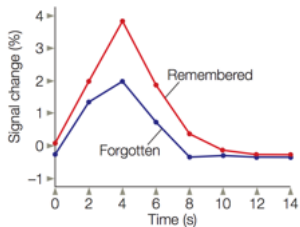


Encode or retrieve

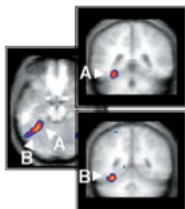
Posterior LIFG



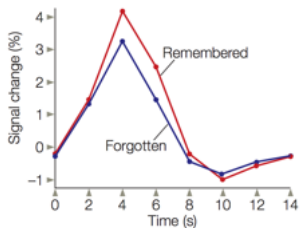
a



Parahippocampal/fusiform gyri



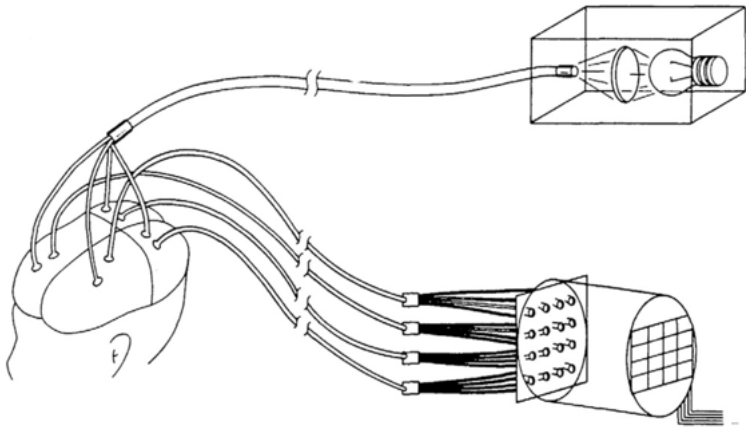
b



Neuroimaging: Function + Structure

functional Near-Infrared Spectroscopy

functional Near-Infrared Spectroscopy



(Ferrari & Quaresima, 2012)

functional Near-Infrared Spectroscopy

functional Near-Infrared Spectroscopy

- fNIRS is a non-invasive imaging method involving the quantification of chromophore concentration resolved from the measurement of near infrared (NIR) light attenuation or temporal or phasic changes.

functional Near-Infrared Spectroscopy

- fNIRS is a non-invasive imaging method involving the quantification of chromophore concentration resolved from the measurement of near infrared (NIR) light attenuation or temporal or phasic changes.
- NIR spectrum light takes advantage of the optical window in which skin, tissue, and bone are mostly transparent to NIR light in the spectrum of 700-900 nm, while hemoglobin (oxy-Hb) and deoxygenated-hemoglobin (deoxy-Hb) are stronger absorbers of light.

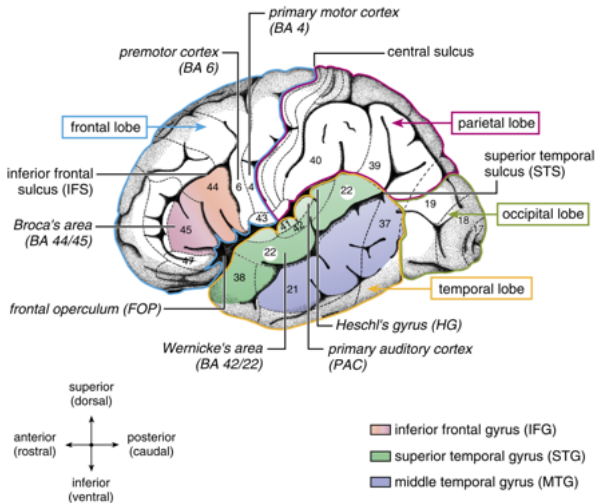
functional Near-Infrared Spectroscopy

- Differences in the absorption spectra of deoxy-Hb and oxy-Hb allow the measurement of relative changes in hemoglobin concentration through the use of light attenuation at multiple wavelengths.

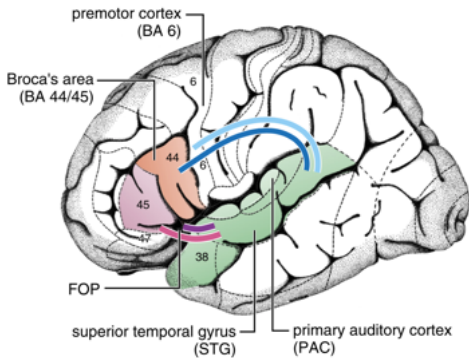
Neuroimaging: Function + Structure

Applying to language

The left hemisphere



Structural connectivities



Dorsal Pathway I

light blue pSTG to premotor cortex
via AF/SLF

Dorsal Pathway II

dark blue pSTG to BA 44
via AF/SLF

Ventral Pathway I

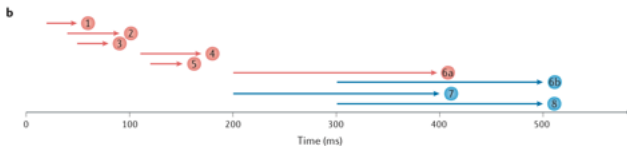
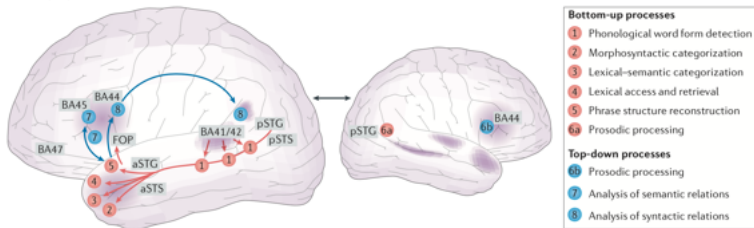
pink STG to BA 45
via EFCS

Ventral Pathway II

purple antSTG to FOP
via UF

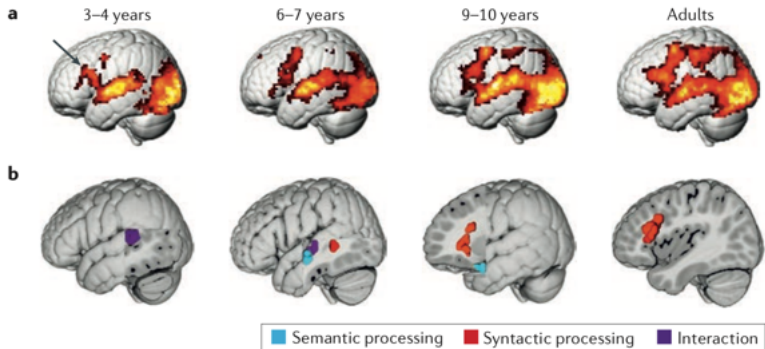
The adult auditory language comprehension network

a Language comprehension in adults



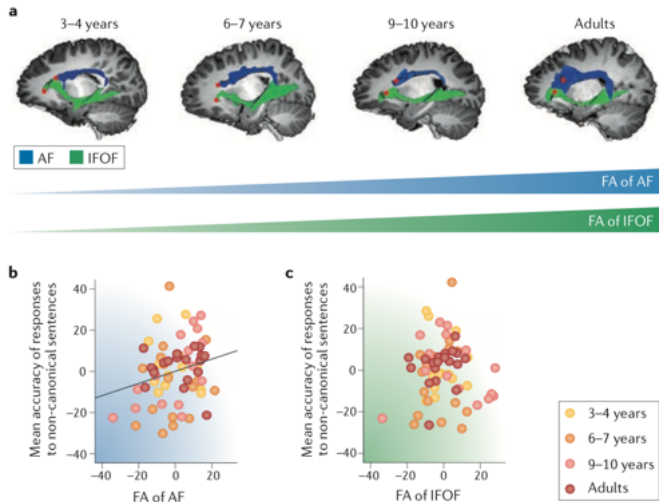
(Skeide & Friederici, 2016)

The segregation of syntax from semantics



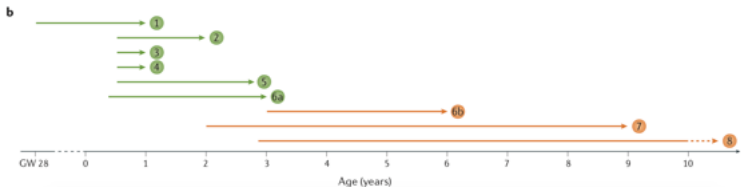
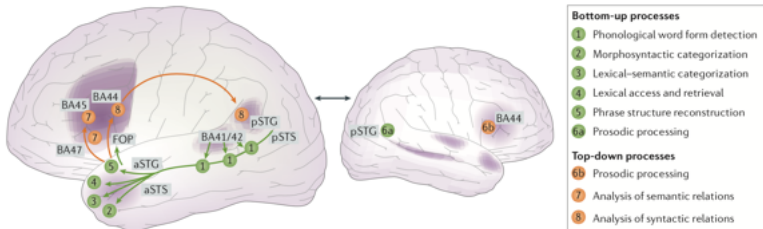
(Skeide & Friederici, 2016)

The ontogenetic emergence of complex syntax



The evolving cortical circuit

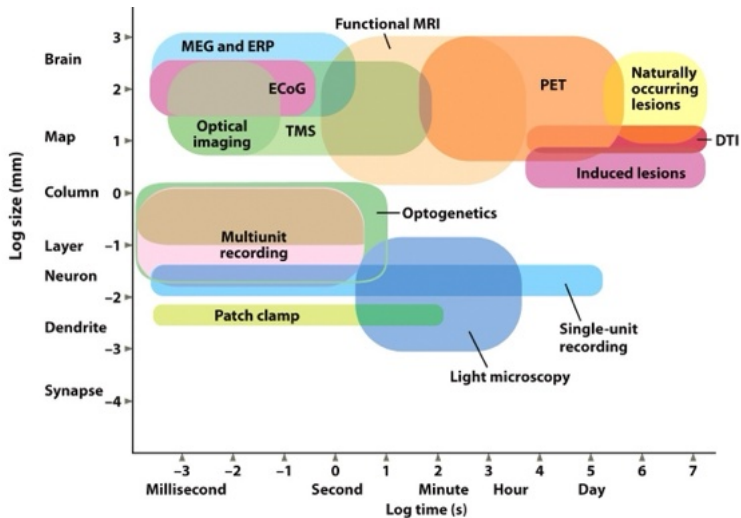
a Developmental trajectories of language and comprehension



(Skeide & Friederici, 2016)

Summary

Summary



(Gazzaniga et al., 2014, p.116)

Thank you

References

References i

- Abbott, A. (2014). Neuroscience: Brains of norway. *Nature*, 514(7521), 154-157. doi: 10.1038/514154a
- Addante, R. J., Watrous, A. J., Yonelinas, A. P., Ekstrom, A. D., & Ranganath, C. (2011). Prestimulus theta activity predicts correct source memory retrieval. *P Natl Acad Sci USA*, 108(26), 10702-10707. doi: 10.1073/pnas.1014528108
- Arthurs, O. J., & Boniface, S. (2002). How well do we understand the neural origins of the fmri bold signal? *Trends Neurosci*, 25(1), 27-31. doi: 10.1016/S0166-2236(00)01995-0
- Blümich, B. (2008). The incredible shrinking scanner. *Sci Am*, 299(5), 92-98. doi: 10.1038/scientificamerican1108-92

References ii

- Brenner, D. J., & Hall, E. J. (2007). Computed tomography —an increasing source of radiation exposure. *New Engl J Med*, 357(22), 2277-2284. doi: doi:10.1056/NEJMra072149
- Chappell, M. H., Ulug, A. M., Zhang, L., Heitger, M. H., Jordan, B. D., Zimmerman, R. D., & Watts, R. (2006). Distribution of microstructural damage in the brains of professional boxers: a diffusion mri study. *J Magn Reson Imaging*, 24(3), 537-42. doi: 10.1002/jmri.20656
- Cogan, G. B., Thesen, T., Carlson, C., Doyle, W., Devinsky, O., & Pesarán, B. (2014). Sensory-motor transformations for speech occur bilaterally. *Nature*, 507(7490), 94-98. doi: <http://doi.org/10.1038/nature12935>

References iii

- DeArmond, S. J., Fusco, M. M., & Dewey, M. M. (1989). *Structure of the human brain: A photographic atlas* [Book]. Oxford University Press.
- de Leeuw, F. E., Barkhof, F., & Scheltens, P. (2005). Progression of cerebral white matter lesions in alzheimer's disease: a new window for therapy? *J Neurol Neurosurg Psychiatry*, 76(9), 1286-8. doi: 10.1136/jnnp.2004.053686
- Dronkers, N. F., Plaisant, O., Iba-Zizen, M. T., & Cabanis, E. A. (2007). Paul broca's historic cases: High resolution mr imaging of the brains of leborgne and lelong. *Brain*, 130(5), 1432-1441. doi: 10.1093/brain/awm042

References iv

- Ferrari, M., & Quaresima, V. (2012). A brief review on the history of human functional near-infrared spectroscopy (fnirs) development and fields of application. *Neuroimage*, 63(2), 921-35. doi: 10.1016/j.neuroimage.2012.03.049
- Friederici, A. D. (2011). The brain basis of language processing: From structure to function. *Physiol Rev*, 91(4), 1357-1392. doi: 10.1152/physrev.00006.2011
- Gazzaniga, M. S., Ivry, R. B., & Mangun, G. R. (2014). *Cognitive neuroscience: The biology of the mind* (4th ed.) [Book]. New York, NY: W.W. Norton & Company.
- Gerrig, R. J. (2013). *Psychology and life* (20th ed.) [Book]. Cambridge, MA: Person Education.

References v

- Gonzalez Andino, S. L., & Grave de Peralta Menendez, R. (2012). Coding of saliency by ensemble bursting in the amygdala of primates. *Front Behav Neurosci*, 6, 38. doi: 10.3389/fnbeh.2012.00038
- Hagoort, P., Brown, C., & Groothusen, J. (1993). The syntactic positive shift (sps) as an erp measure of syntactic processing. *Language and Cognitive Processes*, 8(4), 439-483. doi: 10.1080/01690969308407585
- Hannula, D. E., Simons, D. J., & Cohen, N. J. (2005). Imaging implicit perception: promise and pitfalls. *Nat Rev Neurosci*, 6(3), 247-255. doi: 10.1038/nrn1630

References vi

- Hofer, S., & Frahm, J. (2006). Topography of the human corpus callosum revisited—comprehensive fiber tractography using diffusion tensor magnetic resonance imaging. *Neuroimage*, 32(3), 989-994. doi: 10.1016/j.neuroimage.2006.05.044
- Ingalhalikar, M., Smith, A., Parker, D., Satterthwaite, T. D., Elliott, M. A., Ruparel, K., ... Verma, R. (2013). Sex differences in the structural connectome of the human brain. *Proceedings of the National Academy of Sciences*, 111(2), 823-8. doi: <http://doi.org/10.1073/pnas.1316909110>
- Kutas, M., & Federmeier, K. D. (2011). Thirty years and counting: finding meaning in the n400 component of the event-related brain potential (erp). *Annu Rev Psychol*, 62, 621-47. doi: 10.1146/annurev.psych.093008.131123

References vii

- Kutas, M., & Hillyard, S. A. (1980). Reading senseless sentences: Brain potentials reflect semantic incongruity. *Science*, 207(4427), 203-205. doi: 10.2307/1683915
- Le Bihan, D. (2003). Looking into the functional architecture of the brain with diffusion mri. *Nat Rev Neurosci*, 4(6), 469-80. doi: 10.1038/nrn1119
- Martini, F. H., Timmons, M. J., Tallitsch, R. B., Ober, W. C., Ober, C. E., Welch, K., & Hutchings, R. T. (2015). *Human anatomy* (8th ed.) [Book]. Pearson Education, Inc.
- Mesgarani, N., Cheung, C., Johnson, K., & Chang, E. F. (2014). Phonetic feature encoding in human superior temporal gyrus. *Science*, 343(6174), 1006-10. doi: <http://doi.org/10.1126/science.1245994>

References viii

- Mori, S., & Zhang, J. (2006). Principles of diffusion tensor imaging and its applications to basic neuroscience research. *Neuron*, 51(5), 527-39. doi: 10.1016/j.neuron.2006.08.012
- Pessiglione, M., Seymour, B., Flandin, G., Dolan, R. J., & Frith, C. D. (2006). Dopamine-dependent prediction errors underpin reward-seeking behaviour in humans. *Nature*, 442(7106), 1042-5. doi: 10.1038/nature05051
- Quiroga, R. Q., Reddy, L., Kreiman, G., Koch, C., & Fried, I. (2005). Invariant visual representation by single neurons in the human brain. *Nature*, 435(7045), 1102-7. doi: 10.1038/nature03687

References ix

- Rampon, C., Tang, Y.-P., Goodhouse, J., Shimizu, E., Kyin, M., & Tsien, J. Z. (2000). Enrichment induces structural changes and recovery from nonspatial memory deficits in *ca1 nmdar1*-knockout mice. *Nat Neurosci*, 3(3), 238-244.
- Ridding, M. C., & Rothwell, J. C. (2007). Is there a future for therapeutic use of transcranial magnetic stimulation? *Nat Rev Neurosci*, 8(7), 559-567.
- Skeide, M. A., & Friederici, A. D. (2016). The ontogeny of the cortical language network. *Nat Rev Neurosci*, 17(5), 323-32. doi: 10.1038/nrn.2016.23

References x

- Swaab, T., Brown, C., & Hagoort, P. (1997). Spoken sentence comprehension in aphasia: Event-related potential evidence for a lexical integration deficit. *Journal of Cognitive Neuroscience*, 9(1), 39-66. doi: 10.1162/jocn.1997.9.1.39
- Tye, K. M., Prakash, R., Kim, S.-Y., Fenno, L. E., Grosenick, L., Zarabi, H., ... Deisseroth, K. (2011). Amygdala circuitry mediating reversible and bidirectional control of anxiety. *Nature*, 471(7338), 358-362. doi: <http://www.nature.com/nature/journal/v471/n7338/abs/10.1038-nature09820-unlocked.html#supplementary-information>
- Vitali, P., Migliaccio, R., Agosta, F., Rosen, H. J., & Geschwind, M. D. (n.d.). Neuroimaging in dementia. In *Seminars in neurology* (Vol. 28, p. 467-483). © Thieme Medical Publishers.

References xi

- Vrba, J., & Robinson, S. E. (2001). Signal processing in magnetoencephalography. *Methods*, 25(2), 249-71. doi: 10.1006/meth.2001.1238
- Wagner, A. D., Schacter, D. L., Rotte, M., Koutstaal, W., Maril, A., Dale, A. M., ... Buckner, R. L. (1998). Building memories: Remembering and forgetting of verbal experiences as predicted by brain activity. *Science*, 281, 1188-1191.
- Wagner, T., Valero-Cabre, A., & Pascual-Leone, A. (2007). Noninvasive human brain stimulation. *Annu Rev Biomed Eng*, 9, 527-65. doi: 10.1146/annurev.bioeng.9.061206.133100